

# *Rare case of an isolated scaphoid congenital megalourethra: before and after reconstruction*

Miyad Movassaghi, MD,<sup>1</sup> Rainjade Chung, MD,<sup>1</sup> George W. Moran, MD,<sup>1</sup>  
Christina P. Carpenter, MD<sup>1,2</sup>

<sup>1</sup>Department of Urology, Columbia University Irving Medical Center, New York, New York, USA

<sup>2</sup>Division of Pediatric Urology, Columbia University Irving Medical Center, Morgan Stanley Children's Hospital, New York, New York, USA

---

MOVASSAGHI M, CHUNG R, MORAN GW, CARPENTER CP. Rare case of an isolated scaphoid congenital megalourethra: before and after reconstruction. *Can J Urol* 2022;29(5):11326-11328.

*Congenital megalourethra, first described in 1955, is a rare urethral anomaly resulting from dysgenesis of the penile corpus spongiosum, with or without corpus cavernosum involvement, leading to dilatation of the penile urethra. Presentations come in two forms, scaphoid and fusiform, with the former being more common and resulting from*

*deficient or absent corpus spongiosum. Fusiform types are much rarer, and consist of absence of both the corpus spongiosum and cavernosum.<sup>3</sup>*

*Here, we present a case involving the surgical correction of an isolated scaphoid-type congenital megalourethra with significantly improved postoperative cosmetic and functional outcomes.*

**Key Words:** congenital megalourethra, urethroplasty, scaphoid-type, urethral dilation

---

## Introduction

Congenital megalourethra, first described in 1955<sup>1</sup> is an extremely rare urethral anomaly resulting from dysgenesis of the penile corpus spongiosum, with or without corpus cavernosum involvement, leading to dilatation of the penile urethra.<sup>2,3</sup> Presentations come

in two forms, scaphoid and fusiform, with the former being more common and resulting from deficient or absent corpus spongiosum. Fusiform types are much rarer, and consist of absence of both the corpus spongiosum and cavernosum.<sup>3</sup> Although more often associated with other congenital anomalies, isolated megalourethras do occur and can cause significant voiding dysfunction, as well patient and parental distress.

Here, we present a case involving the surgical correction of an isolated scaphoid-type congenital megalourethra with significantly improved post-operative cosmetic and functional outcomes.

---

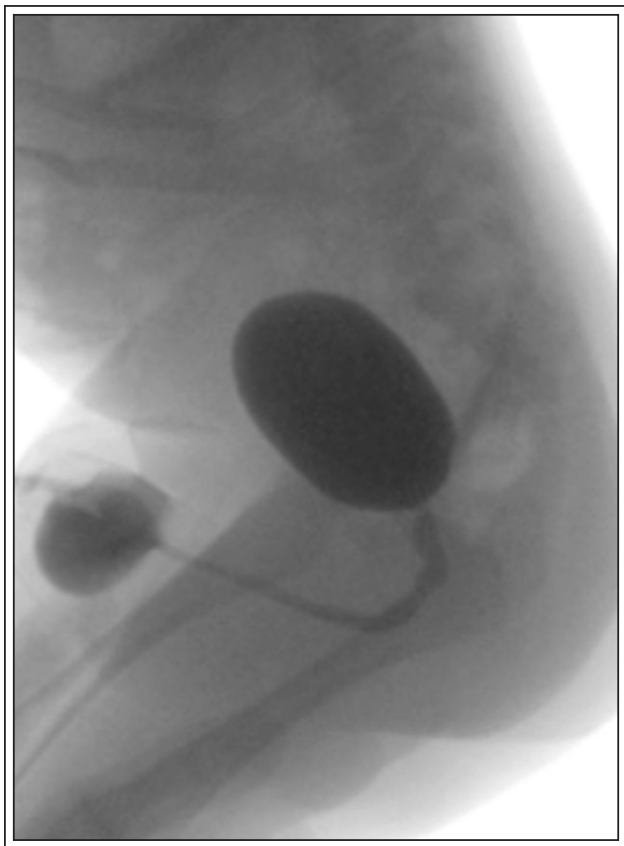
Accepted for publication July 2022

Address correspondence to Dr. Miyad Movassaghi, Dept. of Urology, Columbia University Irving Medical Center, 177 Fort Washington Avenue, New York, NY 10032 USA

## Case presentation

A 10-month old boy initially presented to the office at 14 days of life with complaints of constant dribbling of urine and ballooning of the ventral surface of the penis during voiding since birth. This swelling persisted even after micturition and had to be manually compressed to empty all remaining urine from the dilated foreskin, Figure 1. Although he had normal voiding volumes, his urinary stream lacked force and would spray with marked sideways deviation. He had no history of urinary tract infections, obstruction or congenital genitourinary, or other anatomical malformations.

The remainder of his external genital examination was normal with bilateral descended testicles and orthotopic urethral meatus. Pre and postnatal ultrasounds of the kidneys and bladder were normal. Voiding cystourethrography (VCUG), Figure 1 at 2 months of age revealed dilatation and pooling of urine in the distal penile urethra without any further

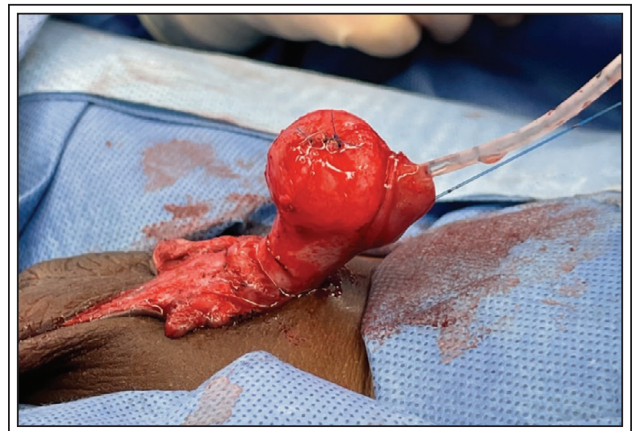

**Figure 1.** VCUG demonstrating an isolated scaphoid-type megalourethra with ventral dilation of pendulous urethra.

structural abnormalities or vesicoureteral reflux. To minimize risks associated with general anesthesia, the decision was therefore made to proceed with a urethroplasty after 6 months of age.

Under general anesthesia, we began with cystourethroscopy, which revealed a dilated penile urethra, normal posterior urethra, and normal bladder. We then proceeded by placing an 8 French feeding tube, and used this to dilate the distal urethral defect with saline, Figure 2. Then, with the feeding tube in place, a standard subcoronal circumcising incision was made circumferentially. Particular care was taken along the ventral aspect, and the megalourethra was periodically filled with saline to help guide dissection.

After the extent of the megalourethra was demarcated, it was incised in the midline. This revealed redundant urethral mucosa with a very thick outer rind. The urethra was adequately mobilized from this outer tissue before excess urethral tissue was excised. A urethroplasty was then performed in a running subcuticular fashion using 7-0 PDS suture. Tubularization was performed with an 8fr catheter in place. After completion, an angiocatheter was inserted adjacent to the catheter, and saline was passed to confirm a watertight closure. The de-mucosalized outer tissue was then used for second layer coverage in a vested fashion – that on the patient's right side was folded over the urethroplasty and secured using interrupted 6-0 PDS sutures, and then that on the patient's left side was similarly folded over and secured. To correct skin placement on the penis, a simple scrotoplasty was performed. The remainder of the circumcision was closed with interrupted stitches. The incision was covered with Dermabond and Coban was placed around the penis. A double diaper was then placed for catheter drainage.



**Figure 2.** Intraoperative circumferential incision with dissection of foreskin and filling of megalourethra.



**Figure 3.** Postoperative follow up at 3 months. Patient voiding without evidence of ventral urethral outpouching.

The postoperative period was uneventful and the catheter was removed 11 days later. The patient returned for his 3-month follow up with a well healed incision. His mother reported a normal urinary stream that was straight without any ventral bulging during or after voiding, Figure 3. Given the absence of any coexisting congenital GU abnormalities on pre and postnatal imaging, no surveillance imaging was required during follow ups.

## Discussion

Megalourethra is a rare congenital anomaly, characterized by either a deficient corpus spongiosum alone (scaphoid-type) or in combination with lack of the corpora cavernosa (fusiform-type).<sup>2,4</sup> Although the exact embryological cause is not clearly understood, the most common cause of this urethral malformation is thought to be either an arrest in the embryogenesis of the mesenchymal tissues of the phallus<sup>5</sup> or arrested or delayed canalization of the distal urethra.<sup>4,6</sup>

Cases of isolated megalourethras have been reported,<sup>5,7</sup> although their presentation is much less common (less than 15% of cases). More commonly, and in as high as 78% of cases as reported by Jones et al, megalourethras are associated with other congenital anomalies, including cardiac, genitourinary, and gastrointestinal malformations or deformities.<sup>2</sup> Abnormalities of the genitourinary system are the most common and include hydronephrosis, vesicoureteral reflux, duplication of the urethra, megoureter, hypospadias, posterior urethral valves, renal agenesis, prune-belly syndrome, and undescended testes.<sup>8</sup> In one of the largest case series and literature reviews to date, congenital megalourethra was reported to be most commonly associated with bilateral hydronephrosis (42% of cases), renal dysplasia (14% of cases), megacystis (52% of cases), bilateral hydronephrosis (58% of cases), hypospadias (8% of cases), and severe oligohydramnios/anhydramnios (28% of cases).<sup>8</sup> In approximately half of these patients, extra-urogenital anomalies were also identified.<sup>8,9</sup> In our patient, no other congenital anomalies were present.

Regardless of their presentation, no standard surgical technique has been identified for treatment of megalourethras, and management described in the literature has varied depending on the type and the presence or absence of associated congenital anomalies.<sup>1</sup> Whether urethroplasty is done in a single or multi-staged approach, outcomes mostly depend on the age of presentation and general condition of the patient prior to surgery. In our case of an isolated scaphoid type of megalourethra, a reduction urethroplasty provided excellent cosmetic and functional results. □

## References

1. Nesbitt TE. Congenital megalourethra. *J Urol* 1955;73(5):839-842.
2. Zugor V, Schrott KM, Schott GE. A complex case of megalourethra and its repair. *J Pediatr Urol* 2006;2(6):592-595.
3. Amsalem H, Fitzgerald B, Keating S et al. Congenital megalourethra: prenatal diagnosis and postnatal/autopsy findings in 10 cases. *Ultrasound Obstet Gynecol* 2011;37(6):678-683.
4. Puri A, Pal DK. Congenital megalourethra: a case report of an isolated delayed presentation. *Int J Adolesc Med Health* 2016;28(1):115-117.
5. Jones EA, Freedman AL, Ehrlich RM. Megalourethra and urethral diverticula. *Urol Clin North Am* 2002;29(2):341-348,vi.
6. Stephens FD, Fortune DW. Pathogenesis of megalourethra. *J Urol* 1993;149(6):1512-1516.
7. Mohan CG, Prakash SV, Kumar VV, Babu RG. Isolated megalourethra: A rare case report and review of literature. *J Indian Assoc Pediatr Surg* 2014;19(3):178-180.
8. Moaddab A, Sananes N, Hernandez-Ruano S et al. Prenatal diagnosis and perinatal outcomes of congenital megalourethra: a multicenter cohort study and systematic review of the literature. *J Ultrasound Med* 2015;34(11):2057-2064.
9. Chao AS, Chang YL, Hsieh PC. Prenatal diagnosis of congenital megalourethra with imperforate anus. *BMC Pediatr* 2019;19(1):123.