

# *Oncogene targeted therapy for metastatic primary scrotal melanoma*

Blair Stocks, MD,<sup>1</sup> Hunter Fuentes, MD,<sup>1</sup> Zachary McDowell, MD,<sup>1</sup>  
Michael Brooks, MD,<sup>1,2</sup> Jeffrey A. Jones, MD<sup>1,2</sup>

<sup>1</sup>Scott Department of Urology, Baylor College of Medicine, Houston, Texas, USA

<sup>2</sup>Michael E. DeBakey Veterans Administration Medical Center, Houston, Texas, USA

---

STOCKS B, FUENTES H, MCDOWELL Z, BROOKS M, JONES J. Oncogene targeted therapy for metastatic primary scrotal melanoma. *Can J Urol* 2021;28(2):10643-10647.

*Primary scrotal melanoma represents the rarest genitourinary malignancy. We describe the 25th reported case. The 79-year-old patient presented with a rapidly enlarging right cutaneous scrotal mass which after local excision demonstrated pT4b nodular malignant melanoma (BRAF V600E mutation positive). The patient underwent*

*wide local excision of his hemiscrotum and inguinal lymph node dissection demonstrating nodes positive for melanoma (pN2b). Postoperatively, the patient developed a left sided malignant pleural effusion (M1b). Per American Joint Commission Cancer staging, BRAF mutant targeted therapy (dabrafenib) was initiated. This case documents the first instance in which metastatic scrotal melanoma will be treated with oncogene targeted therapy.*

**Key Words:** primary scrotal melanoma, BRAF V600E mutation, Dabrafenib

---

## Introduction

The incidence of cutaneous melanoma in the United States continues to rise - from 1993 to 2016, the annual incidence has increased from 14 to 22 cases per 100,000 US citizens per year.<sup>1</sup> Although the majority of cutaneous melanoma presents as localized disease and demonstrates a 5 year survival rate approaching 99%, distant disease is associated with significant

mortality and exhibits a 5 year survival rate of just 25%.<sup>1</sup> Despite the tremendous efforts of basic science and translational researchers, clinical dermatologists, medical oncologists, and public health experts, an unmet need to better understand, treat, and prevent this aggressive disease still exists.

Melanoma of the genitourinary (GU) system is rare and accounts for just 0.2%-1.0% of all annual cases.<sup>2</sup> It can arise anywhere within the male or female genital cutaneous, genital mucosal, or urinary tracts. Compared to typical cutaneous melanomas, GU melanomas tend to present at more advanced stages and are more clinically aggressive. Statistically, 5 year median overall survival (mOS) rates remain poor: 15% for vaginal, 18% for urinary tract, 53% for external

---

Accepted for publication February 2021

Address correspondence to Dr. Jeffrey A. Jones, Department of Urology, Baylor College of Medicine, 2002 Holcombe Blvd., Houston, TX 77030 USA

female genitalia, and 69% for male external genitalia.<sup>3</sup> Etiologic risk factors for GU melanoma remain poorly characterized especially so in that these areas tend to be protected from ultraviolet exposure. Leading theories suggest that chronic inflammatory disease, viral infection, or chemical irritants may play a role in the progression of GU melanoma, however data are limited.<sup>4</sup> Overall, detection of melanoma of the GU system continues to rely on meticulous physician and/or self-performed GU exams and requires expedient work up and treatment.

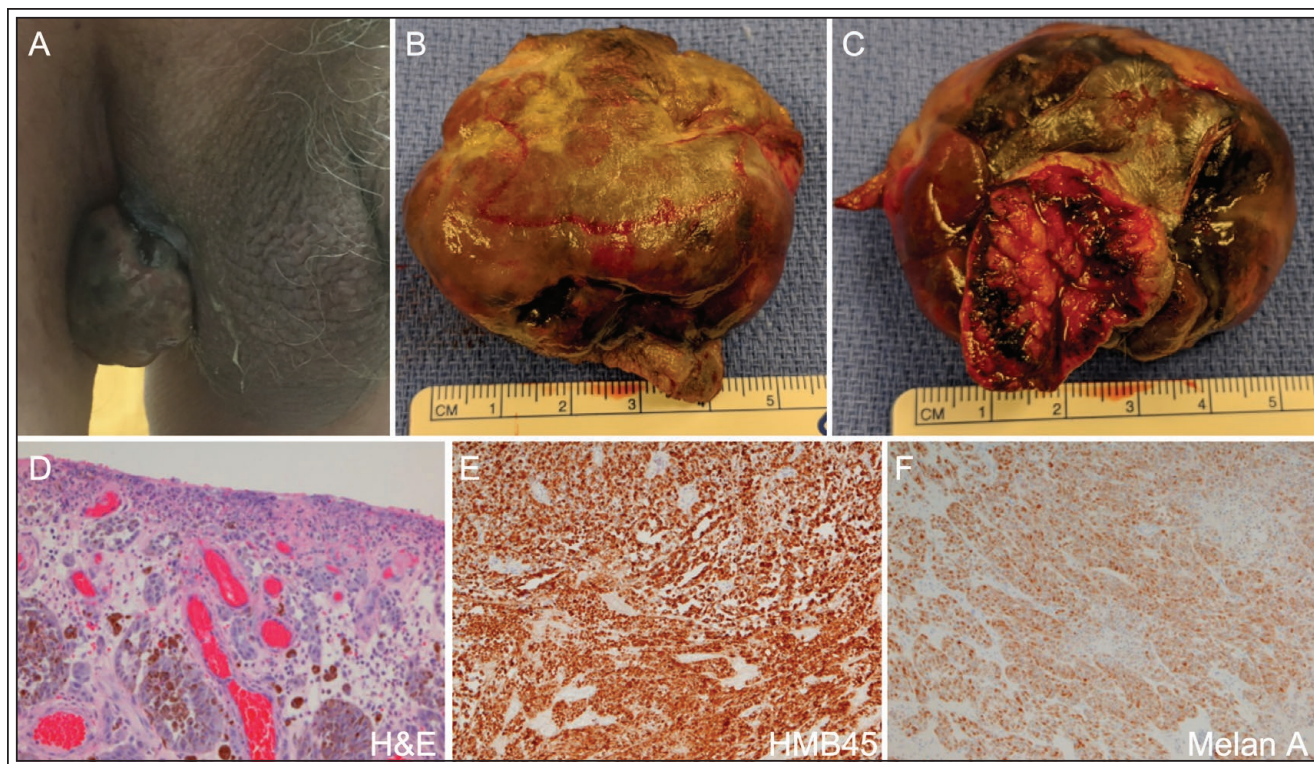
A revolution in the treatment of advanced melanoma was realized in the late 2000s, when the mOS of patients with Stage IV malignant melanoma (per American Joint Commission Cancer [AJCC] staging) approached just 7.7 months despite aggressive chemotherapeutic regimens.<sup>5</sup> Identification of the B-raf-*proto* oncogene (BRAF) and mitogen-activated protein kinase (MEK) pathways, associated melanoma specific mutations (BRAF: V600E, V600K), and mutant oncogene targeted small molecule inhibitors (BRAF vemurafenib, dabrafenib, encorafenib; MEK – trametinib, cobimetinib, binimetinib) led to a number of randomized control trials (RCTs) demonstrating significantly prolonged mOS in patients with advanced stage III/IV BRAF-mutant melanoma receiving these small molecule inhibitors. Complementing these findings, an additional number of RCTs demonstrated that use of antibody-based immunotherapies (immune checkpoint inhibitors) targeting programmed death 1 (PD-1; nivolumab), programmed death Ligand 1 (PD-L1; pembrolizumab) as well as cytotoxic T lymphocyte associated protein 4 (CTLA-4; ipilimumab) significantly prolonged the mOS in patients with advanced stage III/IV BRAF-wild type malignant melanoma. Since their introduction in 2011, a comprehensive review of the National Cancer Database of those US patients with stage IV malignant melanoma receiving either immunotherapy or oncogene targeted therapy (n = 1407) demonstrated a mOS of 16.9 months versus 7.7 months prior to the introduction of these therapies.<sup>5</sup> Per these results, guidelines from both National Comprehensive Cancer Network (NCCN) and American Society of Clinical Oncologists (ASCO) now recommend treating resected stage III/IV melanoma with the aforementioned immunotherapies or oncogene targeted therapies, depending on the patient's BRAF mutation status. Herein, we report the first documented case of a patient with stage IV primary scrotal melanoma undergoing treatment with the BRAF-mutant inhibitor dabrafenib.

## Case report

The patient described herein is a 79-year-old Caucasian male who presented to the Michael E. DeBakey Veterans Administration Medical Center (MEDVAMC) in Houston, Texas in November 2019. He presented to the emergency center for concern of a rapidly enlarging right cutaneous scrotal mass associated with mild purulent/serosanguinous discharge and malodor, Figure 1A. After first noticing the mass 1 month prior, he noted painless gradual enlargement, with no other symptoms or complaints. In the emergency room the patient underwent both a scrotal ultrasound and CT pelvis with contrast which demonstrated an elliptical, hypervascular right scrotal mass without associated lymphadenopathy. A urology consultation noted an approximately 3 cm x 4 cm x 5 cm flesh-colored mass attached to the scrotum by a single stalk. He had no associated palpable inguinal lymphadenopathy. Despite a history of atrial fibrillation, prior partial gastrectomy, cholecystectomy, and advanced age, the patient was in overall good health, lived alone, and carried out the majority of his own activities of daily living (Eastern Cooperative Oncology Group Performance Status 0-1).

Approximately 2 weeks after his initial presentation, the patient was taken to the operating room for local excision of the scrotal mass under local anesthesia, Figure 1B: view of the excised scrotal mass seen laterally; Figure 1C: view of the excised scrotal mass seen medially with the truncated stalk. He tolerated the procedure well and was discharged home the same day. Pathology demonstrated pT4b nodular malignant melanoma with a Breslow depth of invasion > 30 mm, Clark's level V, ulceration, lymphovascular invasion, and uninvolved deep tissue margins, Figure 1D: H&E staining demonstrating atypical melanocytic nests; Figures 1E and 1F: Immunohistochemical staining demonstrating HMB45 and Melan-A positivity. The tumor was also positive for pan-melanoma and S-100 which is not shown. The tumor also carried the V600E BRAF mutation.

Per NCCN guidelines, image studies included a whole-body PET scan which demonstrated avid FDG uptake adjacent to the right scrotal excision site, Figure 2A, in the right inguinal lymph nodes, Figure 2B, and in the left lung pleura with a small associated effusion, Figure 2C. After discussion by the MEDVAMC multidisciplinary tumor board, in early February 2020, the patient underwent a wide local excision of his right hemiscrotum and a right inguinal lymph node dissection demonstrating melanoma positive nodes (pN2b), Figure 2D: note the darkly pigmented



**Figure 1.** The scrotal mass in situ as seen on initial presentation in November 2019 (A) Gross anatomy of the excised mass as seen from the lateral orientation (B) and medial orientation with the excised stalk (C). Pathology staining of the excised lesion demonstrating atypical melanocytic nests on H&E staining (D) and positivity for the melanoma markers HMB45 (E) and Melan A (F) using immunohistochemistry (IHC). The lesion was also IHC positive for Pan-Melanoma and S-100 (not shown). All pathology images are magnified at 40x.

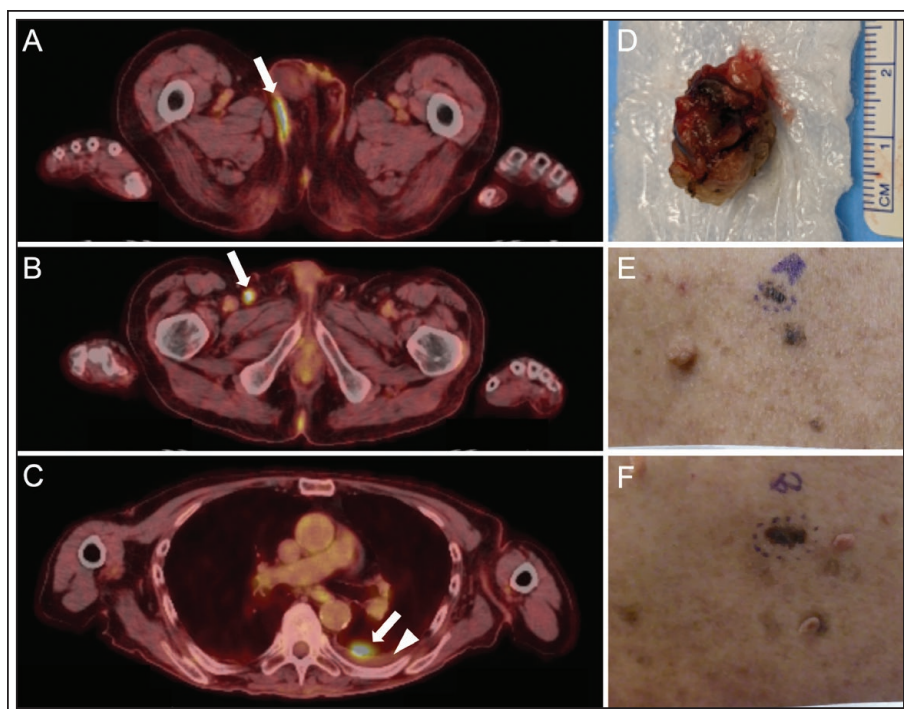
appearance of the node. After the staging surgery, he developed a left sided malignant pleural effusion (M1b) (cytology positive for malignant melanoma) and underwent wide local excision of several melanocytic back nevi, Figures 2E and 2F: pathology consistent with melanoma in situ. Per the NCCN recommendations based on the patient's AJCC TNM staging (stage IV malignant melanoma - T4bN2bM1b) he initiated BRAF targeted therapy with dabrafenib as his tumor carries the BRAF V600E mutation. Immediate addition of the MEK inhibitor trametinib was delayed secondary to the patient's frailty. At the time of submission, the patient is currently following up regularly with the Departments of Urology, Medical Oncology, and Dermatology at MEDVAMC.

## Discussion

Primary scrotal melanoma remains the rarest of all genitourinary malignancies; this case represents only the 25<sup>th</sup> published report of this disease entity.<sup>6</sup> Unlike typical forms of cutaneous melanoma which generally

present at lower stage disease<sup>1</sup> (approximately 83.6% of US patients present with localized AJCC stage I/II disease) scrotal melanoma often presents late in its course and carries a high cancer-specific mortality. Of the known AJCC classifiable cases of primary scrotal melanoma, only 3 patients were found to have stage I/II disease at presentation. Rather so, the majority have presented with advanced stage disease: 10 patients with stage III disease and 5 patients with stage IV disease.<sup>7</sup>

Staging and treatment of primary scrotal melanoma tends to follow cutaneous melanoma guidelines. Wide local excision of the primary lesion remains the gold standard of care and depending on a patient's clinical staging, concomitant sentinel node biopsy, inguinal lymph node dissection, adjuvant immunotherapy, and in some cases local/systemic chemotherapy and radiotherapy have been offered. To date, all patients with primary scrotal melanoma have undergone wide local excision of their primary lesion. Patients with node positive disease have additionally undergone inguinal lymph node dissection followed



**Figure 2.** Whole-body positron emission tomography (PET/CT) demonstrating avid fluorodeoxyglucose (FDG) uptake adjacent to the right scrotal excision site (A, see arrow), in the right inguinal lymph nodes (B, see arrow), and in the left lung pleura (see arrow) with a small associated effusion (see arrowhead) (C). Note that this effusion was later deemed malignant as fluid cytology was positive for malignant melanoma and has required therapeutic tapping. Gross anatomy of the patient's excised right inguinal lymph node demonstrating dark pigmentation consistent with metastatic melanoma (D). Photographs of melanocytic nevi found on the patient's back, pathologically determined classified as melanoma in situ (E and F).

it is important to question whether the pathogenesis of scrotal melanoma differs from that of other forms of cutaneous melanomas which are commonly found in sun-exposed areas. Of particular interest is the finding that the tumor excised in the patient presented herein harbored the BRAF V600E mutation (which ultimately drove the decision to treat with BRAF targeted therapy). Interestingly, the most recent report describing a primary scrotal melanoma in a 30-year-old Caucasian male also identified the BRAF mutation.<sup>6</sup> Although we are unable to comment on the overall prevalence of BRAF mutations in primary scrotal melanomas due to the rarity of the disease and the relatively recent introduction of genomic tumor testing, it is interesting to note that the overall prevalence of BRAF mutations in other cutaneous melanomas approaches 60%. Conversely, it is reported that only 0%-10% of mucosal melanomas carry the BRAF mutation. In comparison to

by chemotherapy regimens including the individual agents listed or in combination thereof: dacarbazine, vincristine, temozolomide, cisplatin. Some patients have also received immunotherapy with either Bacillus Calmette Guerin or interferon alfa 2b. Of those reported cases of primary scrotal melanoma, 60% were reported to die as a direct result of their disease with a mOS of 58.9 months. Of the five documented patients with stage IV disease specifically, each died of their disease 1, 6, 6, 14, and 19 months after diagnosis (calculated mOS of 6 months).<sup>7</sup> Of note, four of these patients were treated for their disease in the pre-immunotherapy and oncogene-targeted therapy era (pre-2011) during which the mOS of all patients with stage IV malignant melanoma was just 7.7 months.<sup>5</sup>

A probable factor contributing to the overall late presentation of primary scrotal melanoma is the stigma surrounding a proper and complete self- or physician-performed genitourinary exam.<sup>6</sup> However,

other male GU melanomas two small case series have evaluated BRAF mutation status in penile melanoma, one finding just 1/5 patients positive,<sup>8</sup> the other 0/12.<sup>9</sup> Further molecular studies have also begun to evaluate the presence of other protooncogenes in GU melanoma including the c-KIT proto-oncogene receptor tyrosine kinase gene (KIT) and the N-ras protooncogene (NRAS). No data exist concerning these markers in primary scrotal melanoma, however, Oxley et al demonstrated that no penile melanomas, within their sample of 12, harbored any c-KIT mutations.<sup>9</sup> Overall, the data are insufficient to conclude whether primary scrotal melanomas are genetically distinct from other forms of cutaneous melanoma, whether the pathogenesis is fundamentally different in the absence of UV exposure, or if there is a more ominous natural history of the disease.

To date one patient has undergone immune checkpoint inhibitor therapy (ipilimumab) in context

of advanced primary scrotal melanoma after failing chemotherapy with dacarbazine and local palliative radiotherapy (the patient died 14 months after his initial surgery).<sup>10</sup> It is important to note however that salvage immune checkpoint inhibition is used in BRAF mutant patients who prove unresponsive to primary oncogene targeted therapy. Although it is too early to determine whether the patient presented herein will respond to dabrafenib, and possibly to combined trametinib therapy, salvage immune checkpoint therapy does remain an option in case of targeted treatment failure.

Ultimately, primary scrotal melanoma is an extremely rare disease entity and often presents with advanced stage disease. Work up and treatment should follow cutaneous melanoma guidelines and advanced disease may benefit from molecular targeted therapies and/or immunotherapy including checkpoint inhibitors. □

---

### References

---

1. National Comprehensive Cancer Network. Cancer Stat Facts: Melanoma of the Skin. Available from URL: <https://seer.cancer.gov/statfacts/html/melan.html>. Accessed April 29<sup>th</sup>, 2020.
2. Rambhia PH, Scott JF, Vyas R et al. Genitourinary melanoma. In: Noncutaneous Melanoma. Scott, JF and Gerstenblith, MR. Brisbane: Codon Publications; 2018:61-81.
3. Bishop KD, Olszewski AJ. Epidemiology and survival outcomes of ocular and mucosal melanomas: a population-based analysis. *Int J Cancer* 2013;134(12):2961-2971.
4. Sanchez A, Rodríguez D, Allard CB et al. Primary genitourinary melanoma: Epidemiology and disease-specific survival in a large population-based cohort. *Urol Oncol* 2015;34(4):166.e7-e14.
5. Dobry AS, Zogg CK, Hodi FS et al. Management of metastatic melanoma: improved survival in a national cohort following the approvals of checkpoint blockade immunotherapies and targeted therapies. *Cancer Immunol Immunother Cii* 2018;67(12):1833-1844.
6. Özkur E, Altunay İK. Primary scrotal melanoma: it is time to destigmatize genital lesions. *An Bras Dermatol* 2019;94(6):721-723.
7. Zikry J, Chapman LW, Korta DZ et al. Scrotal melanoma: a systematic review of presentation, treatment, and outcomes. *Dermatol Surg* 2017;43(6):765-770.
8. Omholt K, Grafström E, Kanter-Lewensohn L et al. KIT pathway alterations in mucosal melanomas of the vulva and other sites. *Clin Cancer Res* 2011;17(12):3933-3942.
9. Oxley JD, Corbishley C, Down L et al. Clinicopathological and molecular study of penile melanoma. *J Clin Pathol* 2011;65(3):228-231.
10. Zucchet LJM, García MÁB, Soriano LL et al. Scrotum melanoma: evolution over one year in this unusual location. *Urol Int* 2016;101(2):232-235.