

Neurofibroma originating from a urachal mass

Spyridon P. Basourakos, MD,¹ Khushabu Kasabwala, MD,¹ Robert Silich, MD,² Juan Miguel Mosquera, MD,^{3,4} Benjamin Choi, MD¹

¹Department of Urology, New York Presbyterian Hospital, Weill Cornell Medical Center, New York, New York, USA

²Department of Plastic and Reconstructive Surgery, New York Presbyterian Hospital, Weill Cornell Medical Center, New York, New York, USA

³Department of Pathology, New York Presbyterian Hospital, Weill Cornell Medical Center, New York, New York, USA

⁴Englander Institute for Precision Medicine, Weill Cornell Medical Center and New York Presbyterian Hospital, New York, New York, USA

BASOURAKOS SP, KASABWALA K, SILICH R, MOSQUERA JM, CHOI B. Neurofibroma originating from a urachal mass. *Can J Urol* 2020;27(5):10407-10410.

Urachal anomalies are rare in the adult population and when diagnosed, are typically malignant. Herein, we report a case of a 61-year-old male who underwent an excision of a urachal mass for a presumed malignancy. Pathologic evaluation demonstrated a neurofibroma.

Neurofibromas are benign peripheral nerve sheath tumors that mostly appear as localized skin tumors and rarely involve the genitourinary system. Neoplastic transformation of neurofibromas is rare but not unheard. To our knowledge, this is the first description of a neurofibroma originating from the urachus.

Key Words: urachal mass, neurofibroma

Introduction

The urachus is a ductal remnant that embryologically originates from the involution of the allantois and the cloaca. The incidence of urachal anomalies is approximately 1 in 5,000 in the adult population and 1 in 150,000 for infants.¹ Embryological remnants of the urachus typically present as patent urachus, diverticulum, urachal sinus and urachal cysts. Urachal cysts are the most common lesion, representing 30% of all urachal anomalies.² Urachal lesions are most frequently recognized and excised in the pediatric population, but they can also be noted in adulthood.

Children commonly present with umbilical drainage or get diagnosed incidentally during abdominal surgery. In contrast, adults tend to present with hematuria and abdominal pain. Urachal anomalies progress differently in pediatric and adult populations, with the latter being at a higher risk for malignancy.³

Neurofibromas are the most common benign tumors of the peripheral nerve sheaths. About 90% of the cases occur sporadically and the remaining cases are associated with neurofibromatosis (NF) type 1 or 2. NF type 1 and 2 are autosomal dominant diseases caused by heterozygous mutations of the NF1 and NF2 genes respectively. Localized sporadic neurofibromas can occur anywhere on the body and have a benign course. In contrast, plexiform neurofibromas carry an increased risk of malignant transformation.⁴ They very rarely appear in the genitourinary system, and when they do, they are related to NF-1 and located in the bladder. NF type 2 has not been reported to affect the genitourinary system.

In this case report, we describe the unusual presentation of a neurofibroma originating from the urachus and imitating a complex mass presumed to be malignant.

Accepted for publication August 2020

Acknowledgements

We thank our colleagues from Pathology and Radiology for their help with reviewing the patient's specimen and imaging.

Address correspondence to Dr. Benjamin Choi, Department of Urology, New York-Presbyterian Hospital, 525 East 68th Street, Starr 900, New York, NY 10065 USA

Case report

A 61-year-old male presented to the clinic with an incidental finding of a urachal mass that was demonstrated on abdominal imaging obtained for abdominal pain. Patient's initial presentation was notable for severe left flank pain, urgency, and hematuria attributed to renal colic. His past medical history was significant for a ureteral stone status post (s/p) laser lithotripsy and enlarged prostate s/p transurethral resection of his prostate. He denied a history of tobacco use or occupational exposure.

Computed tomography (CT) of the abdomen and pelvis demonstrated a lobulated cystic lesion measuring up to 3.4 cm at the anterosuperior aspect of the bladder dome, along the expected course of the urachal remnant. The cystic component of the lesion was compatible with a urachal cyst given that it had mildly greater density relative to simple fluid. The septa of the lesion could not be completely evaluated without pre-contrast phase but findings were suspicious for urachal adenocarcinoma, Figure 1. Thus, magnetic resonance imaging (MRI) of the abdomen and pelvis was performed and demonstrated the same lobulated structure with high signal on T2 phase and no restricted diffusion. The presence of internal septa was suggestive of complex urachal cyst, Figure 2.

Given the complex nature of the mass and concern for malignancy, the risks and benefits of excision were discussed with the patient and the decision was made to undergo surgical resection. The patient underwent an uncomplicated excision of the urachal mass with a partial cystectomy excising the stalk with an en-block umbilical resection and reconstruction

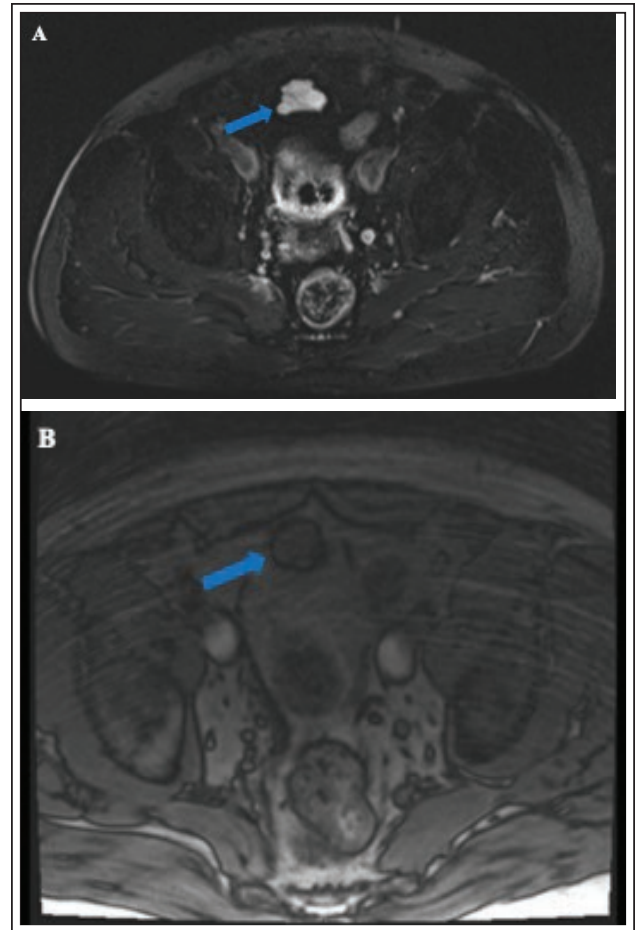


Figure 2. MRI of the abdomen and pelvis demonstrating the urachal lesion at the anterosuperior aspect of the bladder (arrow). **A.** Axial view, T2 weighted image. **B.** Coronal view, T1 weighted image with intravenous contrast.

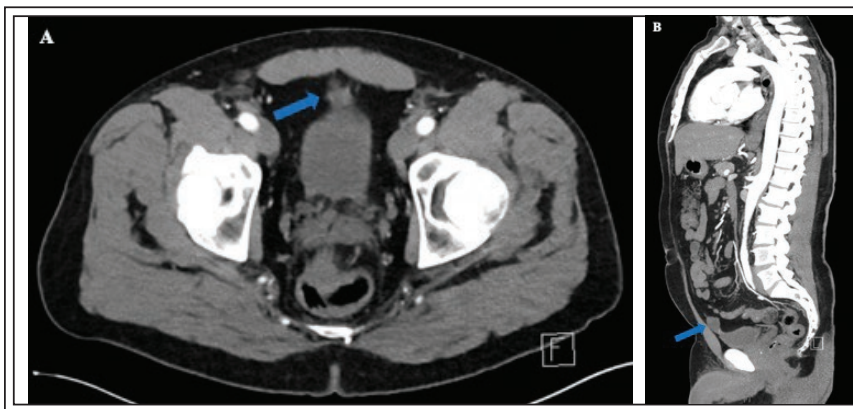


Figure 1. CT of the chest, abdomen and pelvis with intravenous contrast demonstrating the urachal lesion at the anterosuperior aspect of the bladder (arrow). **A.** Axial view. **B.** Coronal view.

with plastic surgery. A Foley catheter was placed at the end of the case. The postoperative course was uncomplicated and the patient was discharged home the following day.

Gross pathological examination revealed a 3.5 cm x 3.4 cm x 1.7 cm, well-circumscribed and lobulated mass, with white-tan, fleshy and glistening cut surface, Figure 3. Excision margins were negative. Histologically, the tumor demonstrated classic features diagnostic of neurofibroma, including loosely arranged spindled-shaped cells with small

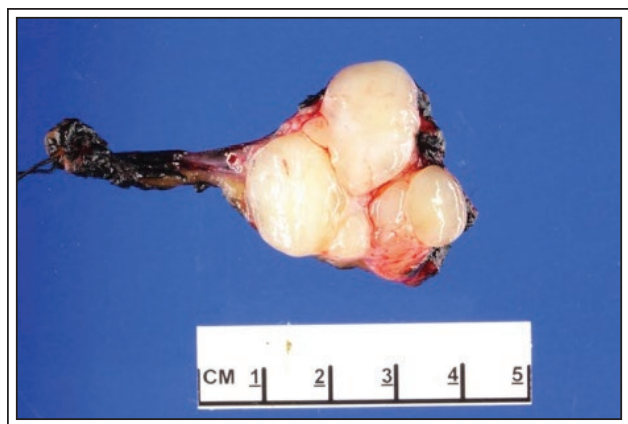

Figure 3. Macroscopic appearance of neurofibroma. A 3.5 cm in greatest dimension lobulated mass was completely excised with clean surgical margins. Cut surface revealed a whitish, uniform and glistening appearance.

amount of cytoplasm, ovoid to elongated nuclei, separated by collagen fibers and myxoid areas, Figure 4.

On postoperative follow up, the patient reported some lower abdominal cramps but otherwise was doing well. Patient was also evaluated by neurology and dermatology for NF and no further treatment was offered in the setting of a benign pathology with no other lesions.

Discussion

The urachus is a canal that links the allantois to the bladder. When the bladder descends in the pelvis during the 5th month of development, the urachus loses its attachment to the umbilicus, its lumen obliterates and finally forms the median umbilical ligament.

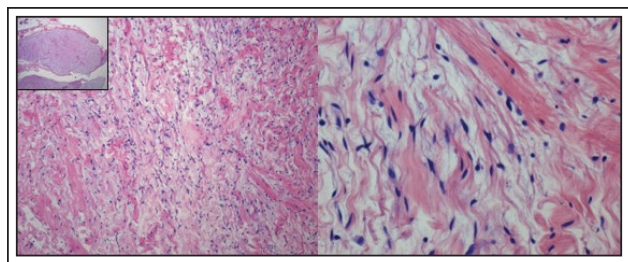


Figure 4. Histopathology of neurofibroma. The lobulated appearance is seen at low power magnification (inset). Tumor is composed of loosely arranged, bland spindled cells (left) with small amount of cytoplasm and elongated nuclei, separated by collagen fibers and myxoid areas (right) (Hematoxylin and eosin stain. Original magnification 20x, 100x, 400x).

Sometimes this process might be incomplete and in that case will give rise to an epithelialized urachal canal that may persist until later in life.⁵ If urachal remnants are not excised in childhood, there is a chance of progression to urachal carcinoma. In a retrospective study from Mayo clinic, it was demonstrated that 50% of the adult patients who presented with urachal lesions were found to have urachal carcinoma. The more worrisome finding was the 5-year cancer specific survival rate that was only 50% in that series of patients.³ Ultimately, 25% of the cystic urachal lesions in adults were cancerous. Thus, monitoring of cystic urachal lesions in the adult population should be discouraged and surgical intervention is recommended, as was done in this case.

In our case, the imaging findings were equivocal for urachal malignancy. Almost 90% of the urachal carcinomas originate from the part of the urachus closer to the bladder and grow cranially.⁶ In clinical practice, ultrasound is most frequently the first imaging modality used to visualize the suspicious lesion. Nevertheless, CT and MRI constitute the gold standard imaging method to evaluate for local disease. The literature suggests that CT findings of midline heterogenous low-attenuation masses may be indicative of malignancy. The presence of calcifications seems to be a strong indicator of malignancy.⁷ On MRI imaging, the finding of focal areas of heterogenous high signal intensity on T2-weighted images raises suspicion of a mucin containing lesion, as noted in our case. However, high signal intensity on T2-weighted images can also be seen in fluid collections and necrosis, making the differential diagnosis via imaging challenging. If the lesion has solid components that demonstrate enhancement on T1-weighted images after administration of intravenous contrast, this is another indicator of malignancy.⁷

The pathology report in our case unexpectedly showed that the urachal lesion was a neurofibroma. To our knowledge, this is the first report of neurofibroma, a benign peripheral nerve sheath tumor, arising from the urachus. Neurofibromas are benign nerve-sheath tumors that most frequently appear as soft, skin-colored nodules, originating from the connective tissues of the peripheral nerve sheaths. Most neurofibromas are solitary and sporadic but can be associated with NF type 1 (NF1) disease, in which case the likelihood of malignant transformation increases with advancing age. Neurofibromas very rarely involve the genitourinary system and there are only a few case reports published in the literature. They most commonly appear in the bladder, but there also reports involving the penis, prostate, urethra and ureter.⁸

Conclusion

Urachal lesions are rare in the adult population and most commonly are discovered incidentally with imaging. The majority of those lesions are malignant and surgical excision constitutes the standard of care. In our case, pathologic evaluation demonstrated a neurofibroma, a benign peripheral nerve sheath tumor that rarely involves the genitourinary system. Neoplastic transformation of neurofibromas is rare but not unheard. To our knowledge, this is the first description of a neurofibroma originating from the urachus. □

References

1. Berman SM, Tolia BM, Laor E et al. Urachal remnants in adults. *Urology* 1988;31(1):17-21.
2. Pesce C, Costa L, Musi L et al. Relevance of infection in children with urachal cysts. *Eur Urol* 2000;38(4):457-460.
3. Ashley RA, Inman BA, Routh JC et al. Urachal anomalies: a longitudinal study of urachal remnants in children and adults. *J Urol* 2007;178(4 Pt 2):1615-1618.
4. Lassmann H, Jurecka W, Lassmann G et al. Different types of benign nerve sheath tumors. Light microscopy, electron microscopy and autoradiography. *Virchows Arch A Pathol Anat Histol* 1977;375(3):197-210.
5. Sheldon CA, Clayman RV, Gonzalez R et al. Malignant urachal lesions. *J Urol* 1984;131(1):1-8.
6. Wong-You-Cheong JJ, Woodward PJ, Manning MA et al. From the archives of the AFIP: Inflammatory and nonneoplastic bladder masses: radiologic-pathologic correlation. *Radiographics* 2006;26(6):1847-1868.
7. Parada Villavicencio C, Adam SZ, Nikolaidis P et al. Imaging of the urachus: anomalies, complications, and mimics. *Radiographics* 2016;36(7):2049-2063.
8. Zugail AS, Benadiba S, Ferlicot S et al. Oddities sporadic neurofibroma of the urinary bladder. A case report. *Urol Case Rep* 2017;14:42-44.