

# *Urologic and endovascular repair of a uretero-iliac artery fistula*

Lior M. Hirsch, BS,<sup>1</sup> Michael J. Amirian, MD,<sup>1</sup> Scott G. Hubosky, MD,<sup>1</sup>  
Akhil K. Das, MD,<sup>1</sup> Babak Abai, MD,<sup>2</sup> Costas D. Lallas, MD<sup>1</sup>

<sup>1</sup>Department of Urology, Thomas Jefferson University Hospital, Philadelphia Pennsylvania, USA

<sup>2</sup>Division of Vascular and Endovascular Surgery, Thomas Jefferson University Hospital, Philadelphia Pennsylvania, USA

---

HIRSCH LM, AMIRIAN MJ, HUBOSKY SG, DAS AK, ABAI B, LALLAS CD. Urologic and endovascular repair of a uretero-iliac artery fistula. *Can J Urol* 2015;22(1):7661-7665.

*Patients with a uretero-iliac artery fistula (UIAF) are at an elevated risk of life-threatening hemorrhage. Identification and treatment of the fistula may be challenging, and*

*requires the combined expertise of a urologist and endovascular specialist. This manuscript provides a list of equipment needed and describes our technique for diagnosing and treating a UIAF.*

**Key Words:** uretero-iliac artery fistula (UIAF), ureteroarterial fistula (UAF)

---

## Introduction

Uretero-iliac artery fistula (UIAF) is an uncommon, yet morbid condition owing to potential massive blood loss. While rare, an increasing incidence of UIAF has been reported in recent literature.<sup>1</sup> Some speculate that the increase in incidence reflects the increase in risk factors associated with UIAF, combined with longer general survival.<sup>1,2</sup> Well-known risk factors for the development of UIAF include a history of pelvic surgery, pelvic irradiation, peripheral vascular disease and chronic ureteral stenting.

---

Accepted for publication December 2014

Address correspondence to Dr. Costas D. Lallas, Department of Urology, Thomas Jefferson University Hospital, 1025 Walnut Street, Suite 1112, Philadelphia, PA 19107 USA

Diagnosing a UIAF has proven to be challenging at times, due to the difficulty in demonstrating the fistula preoperatively. While contrast-enhanced computed tomography (CECT) is commonly performed preoperatively, its sensitivity is too low to recommend it as first line.<sup>3</sup> In addition, ureteral contrast studies performed intraoperatively may not demonstrate extravasation due to an unfavorable pressure gradient from ureter to artery. While angiography alone may demonstrate the fistula, provocative angiography is the highest sensitivity diagnostic testing for a UIAF, approaching up to 100% sensitivity in one case series.<sup>4</sup> This technique may involve removal of an indwelling ureteral stent, or irritation of the suspected fistula site with back-and-forth motion of a balloon catheter, at the time of angiography to assess for contrast extravasation. However, it is important to note that a negative provocative angiogram does not exclude the

diagnosis of a UIAF, and in such cases the physician must rely on a high index of suspicion.

The use of endovascular stent grafts (i.e. covered stents) for the treatment of UIAF has increased since their reported success in the mid-1990s.<sup>5</sup> Notable benefits of its use compared to vascular bypass include rapid control of the hemorrhage, and avoiding operating in a previously radiated or scared surgical field.<sup>6</sup> Multiple reports have demonstrated good short term and long term results, with a high success rate and low rate of hematuria recurrence within the first year.<sup>1,7</sup>

While there exists proposed diagnostic and treatment algorithms for a UIAF, preparing for the case may pose some unique challenges and no report currently provides detailed recommendations for its management. Given its rarity and unique anatomical location, the diagnosis and treatment of UIAF may at times require the combined expertise of a urologist, endovascular specialist, and open vascular specialist. In this paper, the authors aim to provide a list of recommendations that are indispensable to the management of a patient highly suspected of having a uretero-iliac artery fistula.

## Method and technique

### *Patient selection*

Hematuria is the most common presenting symptom of a UIAF. This does not only include gross hematuria, but also intermittent microscopic hematuria owing to the formation of a temporary blood clot at the site of the fistula.<sup>1</sup> Some patients with episodic hematuria may present with massive hemorrhage occurring at ureteral stent change. In addition, any hematuria causing a significant drop in hemoglobin requiring a blood transfusion must increase the physician's index of suspicion. In many patients hematuria may be the only described symptom, yet others may experience accompanying back pain, urinary retention, and signs of infection. Flank pain lateralized to the fistula site, secondary to obstruction of the ureter by the blood clots, has also been described in the literature.<sup>1,3</sup>

These signs and symptoms combined with the risk factors of previous pelvic surgery, pelvic irradiation, peripheral vascular disease and chronic ureteral stenting should encourage the physician to rule out a UIAF and prepare to take the patient to the endovascular suite for definitive diagnosis and treatment. As mentioned previously, preoperative diagnosis of UIAF can be difficult. With a high index of suspicion, intraoperative contrast studies can aid in the diagnosis, location, and severity of the fistula.

### *Equipment and preparation*

Given the multidisciplinary approach to the treatment of a UIAF, we recommend performing such a procedure in a vascular operating room capable of simultaneous urologic and vascular fluoroscopy. An endovascular specialist who is familiar with the case should be present and available for pelvic arteriography and deployment of the stent graft. In addition, we recommend the vascular team prepare for embolization and/or definitive vascular bypass, in case vascular stenting is unattainable or unsuccessful.

With the risk of significant hemorrhage and an acute drop in hemoglobin, multiple measures should be taken to decrease the morbidity of this procedure. We recommend the anesthesia team be prepared with a rapid transfusion protocol. The following is a list of specific equipment for each team that should be made available during the procedure.

#### Urology:

- Rigid cystoscope
- Ellick bladder evacuator
- 0.038 inch Sensor Guidewire
- Amplatz Super Stiff Guidewire
- Flex-X flexible ureteroscope
- Power irrigation
- 50/50 contrast
- 6 cm X 6 mm X-FORCE U30 ureteroscopic balloon dilation catheter

#### Vascular:

- Bentson Wire Guide (Cook Medical)
- Angled Glidewire
- Angled Glidecath
- VCF catheter
- Rosen wire
- 45 cm 6 French sheath for contralateral access
- Stent graft: Gore Viabahn Endoprosthesis or atrium iCast stent
- Embolic device: embolic coils or plugs
- Vascular closure device: Angio-Seal Evolution
- Major tray for definitive vascular exclusion and bypass procedure

#### Anesthesia:

- General anesthesia with paralysis
- Blood type & crossmatch with 4 units of blood ready
- 2 large bore IVs
- Central venous access
- Arterial line

### *Identification of the UIAF*

After administering general anesthesia to the patient, the patient should be positioned in the dorsal lithotomy

position and prepared in the usual sterile fashion. It is important to prep the patient's genitalia, groin, and abdomen in case definitive vascular bypass is performed. Next, identification of the suspected UIAF should occur in the presence of both the attending urologist and endovascular specialist. Cystoscopy should be performed first using a rigid cystoscope to enter the bladder. If a large amount of clot is present, irrigation should be performed to clear these contents from the bladder.

After performing a complete cystoscopic examination and identifying the ureteral orifice (UO) on the side of the bleeding fistula, the UO should be cannulated with a guidewire. First, a 0.038 inch Sensor Guidewire should be passed under fluoroscopic guidance to the level of the renal pelvis. Utilizing over-the-wire technique, a Flex-X flexible ureteroscope should be advanced to the renal pelvis. For tortuous anatomy, an Amplatz Super Stiff Guidewire may be needed to ease advancement of the ureteroscope. If the renal pelvis is markedly bloody, it should be aspirated in order to try and improve the visibility. A spot fluoroscopy image should be obtained prior to continuing with the procedure. As the ureteroscope is removed down to the level of the pelvic brim, the urologist should note any areas of pulsatile bleeding and mucosal heaping consistent with a UIAF, and such an area should be marked on fluoroscopy with the endovascular specialist present. Contrast power irrigation may be utilized during this part of the procedure in order to try and delineate a contrast extravasation, and confirm the diagnosis of a fistula.

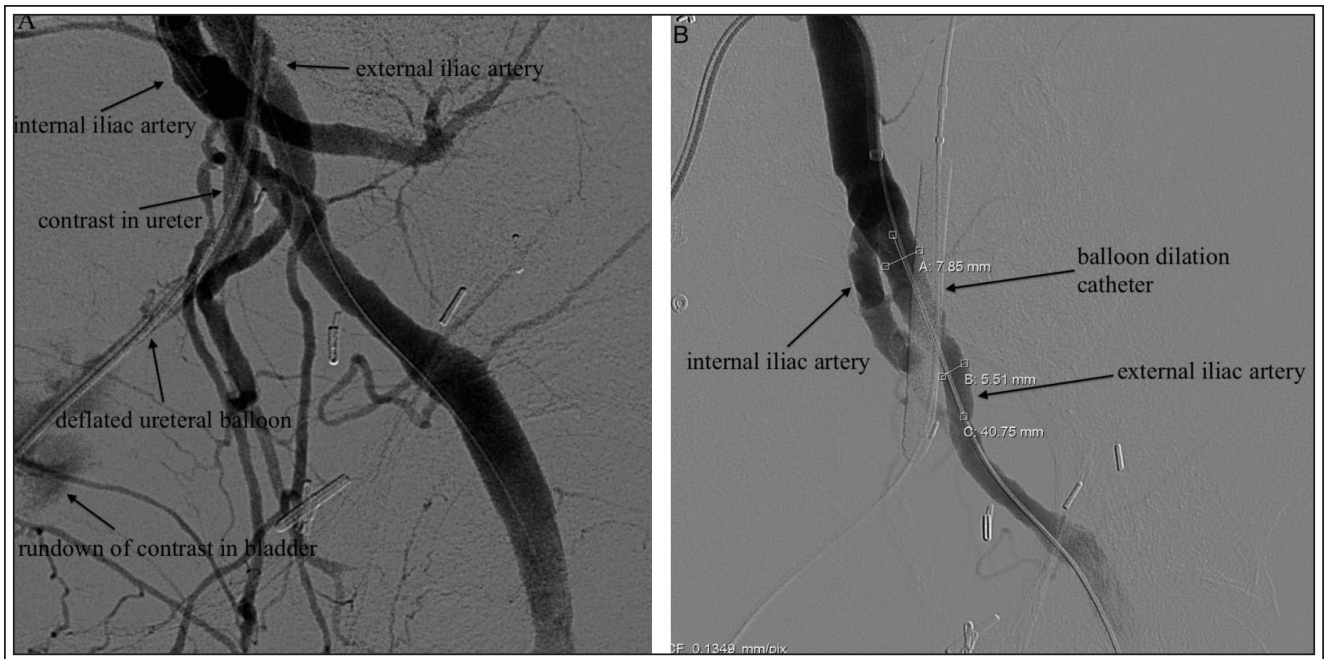
Having identified the location of the UIAF, it necessary to occlude the fistula site with a balloon catheter. Upon removing the ureteroscope distal to the suspected fistula, a significant amount of bright red bleeding may be noted. In this case, the ureteroscope should be removed and a 6 cm X 6 mm X-FORCE U30 Ureteroscopic Balloon Dilation Catheter should be placed using the guidewire. The balloon dilator should be positioned to straddle the bleeding area and insufflated to 6 atmospheres in order to stop the bleeding. Ureteroscopy of the distal ureter should confirm tamponade of the suspected fistula. At any point of this procedure brisk bleeding may be encountered, especially if an indwelling ureteral stent is present at the onset of the case that needs removal. We therefore stress the importance of having the occlusion balloon present and ready from the beginning of the procedure. At this point in time, a Foley catheter should be placed into the bladder and the endovascular specialist should prepare for arteriography and intervention.

### *Arteriography and vascular stent placement*

Under fluoroscopic guidance, the femoral head contralateral to the side of the UIAF should be identified, and the common femoral artery should be accessed using a micropuncture needle in a retrograde manner. Over a Bentson Wire Guide, the micropuncture sheath should be exchanged for a 5 French sheath. Next, an angled Glidewire should be advanced through the common femoral artery and across the aortic bifurcation into the contralateral common iliac artery, ipsilateral to the UIAF. This usually requires a special catheter, such as a VCF catheter, that directs the guidewire into the contralateral common femoral artery. Finally, over the Glidewire an angled Glidecath should be advanced and a pelvic arteriogram performed in order to identify the internal and external iliac arteries.

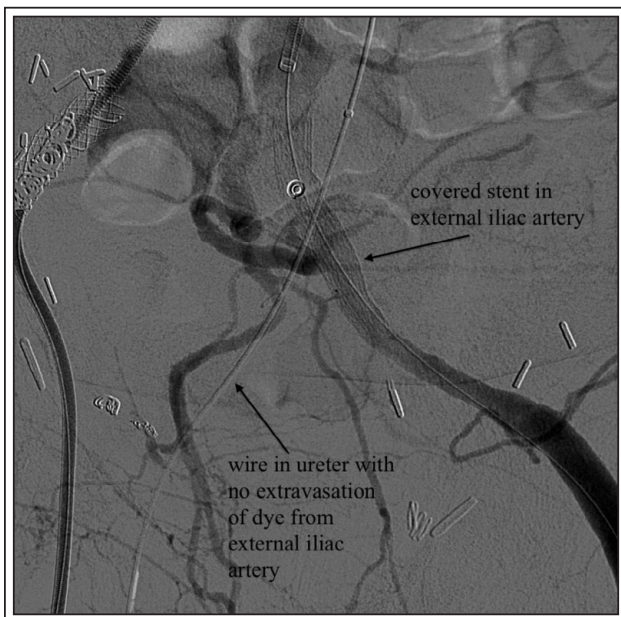After obtaining access to the iliac artery ipsilateral to the UIAF, an internal iliac arteriogram should be performed while deflating the ureteral balloon catheter and agitating the fistula site. Any contrast enhancement of the ureter on fluoroscopy should be noted at this time, confirming the site of the UIAF, Figure 1a. The same process should then be repeated for the external iliac artery on the same side. Once the site of the UIAF has been identified, the ureteral balloon should be inflated to stop the bleeding, Figure 1b. Before proceeding further, the patient should be heparinized to prevent thrombosis during stent graft deployment.

After confirming the fistula site via provocative angiography, over a Rosen wire a long 6 French sheath should be advanced across the aortic bifurcation to the contralateral vessel of interest be it the internal or external iliac artery. Next, a stent graft should be deployed after which it is post-dilated using a balloon. A complete arteriogram should finally be performed subsequent to takedown of the ureteral balloon, to ensure no contrast enhancement of the ureter on fluoroscopy, Figure 2. The available embolization devices can be used either as an adjunct or by themselves if the area in question is not amenable to stenting. The embolization may be a viable option especially when a UIAF involves the internal iliac artery. After confirming proper placement of the stent, the sheath should be backed out through the contralateral external iliac artery and the common femoral artery. If appropriate, a closure device may be used to seal the arteriotomy, and a palpable femoral pulse should be confirmed at the end of the case. In cases where this is not possible, after appropriate time is given for the heparin to wear off, the sheath can be pulled and manual pressure applied to thrombose the arteriotomy site.



**Figure 1.** a) Iliac arteriogram demonstrating extravasation of contrast into the ureter, consistent with a UIAF. A deflated ureteral balloon dilator is noted as well; b) Inflation of the ureteral balloon tamponades the bleeding and no contrast is seen in the ureter.

It is crucial that both the urology team as well as the vascular team be available and work together. The less desirable alternative, especially in the case of external



**Figure 2.** Iliac arteriogram after deployment of an external iliac artery stent. With subsequent takedown of the ureteral balloon, no contrast is seen in the ureter.

iliac artery involvement, would be to temporarily stop the hemorrhage by placing an intravascular balloon while preparing to deploy the stent graft. This option may lead to thrombosis of the more distal vessels that supply one of the lower extremities if the patient is not heparinized properly. On the other hand, untimely heparinization may lead to excessive bleeding in this scenario.

### Postoperative care

During the immediate postoperative period, the patient should be on bed rest in the surgical intensive care unit. Hemoglobin levels and urine output should be closely monitored over the next 24 hours to assess for any hemorrhage and to ensure adequate volume status. For long term care the patient should be started on dual anti-platelet therapy, usually clopidogrel and aspirin 81 mg, for 3 months and then continued on aspirin 81 mg indefinitely. While the stent can develop stenosis over time, the patient should receive regular surveillance and followed long term with ultrasound and vascular lab studies.

### Discussion

Many urologists may feel unprepared to treat a UIAF due to the lack of exposure to this difficult and

uncommon condition. However, with the increase in risk factors and longer survival for genitourinary malignancies, urologists will encounter this condition more often. At our institution, endovascular stenting is the preferred treatment for a UIAF and is performed in collaboration with a vascular surgeon.

While no randomized controlled trials comparing the outcomes of open versus endovascular treatment for UIAF currently exist, there are single center retrospective reviews comparing the evolution of treatment for this condition. In the 1990s, arterial treatment for this condition was primarily by iliac arterial occlusion with extra-anatomic bypass, or direct arterial repair. By the mid-2000s, endovascular stenting became the definitive method of treatment at some centers. At one institution, open repair was associated with an early complication rate of 63%, including the development of enterocutaneous fistulas and superficial wound infections. Comparatively, early complications occurred in approximately 27% of those treated with endovascular repair, including pneumonia, non-ST-segment myocardial infarction, and stent graft thrombosis.<sup>6</sup> Long term complication rates compared between these two treatment options are not yet clearly defined. Some centers have not found a clear advantage for endovascular stenting over open vascular repair, yet have adopted endovascular stenting as the preferred method of treatment due to the high operative risk in patients with a UIAF.<sup>5</sup>

In many centers across the country, endovascular stents were primarily only used for poor surgical candidates. However, since most cases of UIAF are considered unstable owing to significant hemorrhage requiring transfusion, endovascular stents have become the preferred treatment of choice for UIAF. Indications for an open repair include enteric contamination, abscess, the need to preserve pelvic flow because of contralateral occluded iliac artery, and failed endovascular stent grafting.<sup>6</sup>

### Conclusion

The diagnosis and treatment of a UIAF requires a multidisciplinary approach involving a urologist and endovascular specialist. Although an uncommon condition, morbidity may be high from the risk of hemorrhage. It is imperative that the treating physicians coordinate together, perform the case in an endovascular suite, and be prepared for definitive exclusion of the fistula along with a vascular bypass procedure if the endovascular procedure fails to stop the hemorrhage. □

---

### References

---

1. van den Bergh RC, Moll FL, de Vries JP, Lock TM. Arterioureteral fistulas: unusual suspects – systematic review of 139 cases. *Urology* 2009;74(2):251-255.
2. Okada T, Yamaguchi M, Muradi A et al. Long-term results of endovascular stent graft placement of urethroarterial fistula. *Cardiovasc Intervent Radiol* 2013;36(4):950-956.
3. Krambeck AE, DiMarco DS, Gettman MT, Segura JW. Ureteroiliac artery fistula: diagnosis and treatment algorithm. *Urology* 2005;66(5):990-994.
4. Vandersteen DR, Saxon RR, Fuchs E, Keller FS, Taylor LM Jr, Barry JM. Diagnosis and management of urethroiliac artery fistula: value of provocative arteriography followed by common iliac artery embolization and extraanatomic arterial bypass grafting. *J Urol* 1997;158(3 Pt 1):754-758.
5. Kerns DB, Darcy MD, Baumann DS, Allen BT. Autologous vein-covered stent for the endovascular management of an iliac artery-ureteral fistula: case report and review of literature. *J Vasc Surg* 1996;24(4):680-686.
6. Malgor RD, Oderich GS, Andrews JC et al. Evolution from open surgical to endovascular treatment of ureteral-iliac artery fistula. *J Vasc Surg* 2012;55(4):1072-1080.
7. Fox JA, Krambeck A, McPhail EF, Lightner D. Ureteroarterial fistula treatment with open surgery versus endovascular management: long-term outcomes. *J Urol* 2011;185(3):945-950.