

How I Do It: The pudendal nerve block for pediatric ambulatory urologic surgery

Chinonyerem Okoro, MD,^{1,2} Shannon Cannon, MD,³ Daniel Low, BMBS,³ Thomas S. Lendvay, MD³

¹Department of Urology, University of Washington Medical Center, Seattle, WA

²Department of Urology, Temple University Hospital, Philadelphia, Pennsylvania, USA

³Seattle Children's Hospital, Seattle, Washington, USA

OKOROC, CANNONS, LENDVAY TS. How I Do It: The pudendal nerve block for pediatric ambulatory urologic surgery. *Can J Urol* 2021;28(2):10648-10651.

Regional analgesia is an important adjunct for perioperative pain management in the setting of pediatric penile surgeries. Caudal epidural analgesia (CEA) is the most common analgesic technique performed, but it has limitations and associated morbidity. The pudendal nerve block (PNB) is an

effective alternative to CEA with a lower risk profile; in prior examination of the approach, PNB has been demonstrated to have similar postoperative pain control outcomes. We describe our technique and highlight observations made as we have transitioned from CEA to PNB for many patients.

Key Words: pudendal nerve block, regional anesthesia, pediatric urology, pain management

Introduction

Overview of procedure/technology

The vast majority of pediatric urologic procedures are performed in an elective, ambulatory setting; one-third of all surgeries performed by a pediatric urologist address concerns of the prepuce or phallus.¹ Given the prevalence of these surgeries and the context in which they are performed, perioperative pain management is critical to ensuring safe, uneventful recovery and discharge.

Regional nerve blockade is a common and important adjunct in perioperative pain management for pediatric urologic surgeries. For penile surgery such as circumcision or hypospadias, the most common block performed in young males has historically been caudal epidural analgesia (CEA).² A single injection of local anesthetic into the caudal epidural space, this

technique provides reliable analgesia for sub-umbilical operations.³ However, CEA is contraindicated in children with anatomic abnormalities of the lower back and can potentially produce a prolonged motor blockade and/or urinary retention; rare but serious complications have also been described.^{3,4} An alternate regional anesthetic technique that avoids neuraxial access and thus provides a lower morbidity profile would avoid the more serious complications associated with CEA. Furthermore, CEA requires a certain degree of expertise gained from doing a large number of these types of blocks. Penile nerve block is a subcutaneous field block to the dorsal penile nerve or can be performed as a ring block at the base of the penis, but is associated with hematoma formation, structural distortion, local anesthetic systemic toxicity, and inadequate analgesia of the ventral penis.^{5,6}

The pudendal nerve arises from the anterior rami of the second to fourth sacral segments, travels through the lesser sciatic foramen and pudendal canal before branching into the dorsal nerve of the penis or clitoris, the perineal nerve, and the inferior rectal nerve. The pudendal nerve block (PNB) is a local field block of the dorsal nerve, which provides somatosensory input for the penis.⁷ A PNB utilizes a local anesthetic delivered to the tissues adjacent to the dorsal nerve, using perineal

Accepted for publication February 2021

A video clip is available online at www.canjurol.com

Address correspondence to Dr. Chinonyerem Okoro, Department of Urology, Temple University Hospital, 3509 N. Broad Street, Boyer Pavilion, 6th Floor, Philadelphia, PA 19140 USA

access obtained either through landmark orientation or ultrasound guidance.

Relevant historical studies

The PNB has been compared to both the CEA and penile nerve blocks in pediatric urology patients. In a randomized double-blind study, Tutuncu et al compared postoperative pain for 85 children undergoing surgical circumcision and demonstrated that patients who received PNB had significant decrease in pain scores and required less additional analgesic medication than patients who received penile nerve block.⁶ Naja et al examined rates of analgesic rescue in 80 children undergoing hypospadias repair who were randomized to receive either CEA or PNB; patients who received PNB achieved a 50% lower analgesic rescue rate and used less rescue medication during the first 24 hours.⁸ A subsequent comparison of CEA and PNB in a hypospadias population demonstrated decreased postoperative pain, less need for additional analgesia and higher satisfaction rates in those who received PNB.⁹ Although ultrasound-guided PNB is more often discussed, landmark directed PNB has been described as a safe and simple procedure that can provide accurate diagnosis and treatment for pudendal neuralgia.¹⁰

In this report, we detail our initial institutional experience with PNB, which was adopted as a standard approach for regional analgesia in pediatric penile surgeries performed at our ambulatory surgery center (ASC). We describe both ultrasound-guided PNB and landmark-directed PNB techniques in detail, as a primer for surgeons and anesthesiologists desiring to utilize this analgesic option in their practice.

Method and technique

Ultrasound-guided PNB

After general anesthesia induction and airway control, the patient is positioned supine, hips in abduction, flexed legs, and soles of the feet joined (“frog leg position”). A towel roll or gel roll of appropriate size is then placed below each knee for support, allowing for adequate exposure of the perineum. Additionally a small bump may be placed under the hips to elevate the perineum. Ultrasound (US) images are then obtained. The ischial tuberosity is first identified with palpation and confirmed via US as a hyperechoic semicircle with a hypoechoic bone shadow inferior to it. With the long axis of the US probe on the ischial tuberosity, the probe is moved medially until the hypoechoic shadow of the rectum is also visualized, Figure 1. The ischiorectal fossa is located between the ischium, laterally and the rectum, medially. The pudendal artery can be searched using color Doppler, however due to its small caliber this may not always be seen. After careful skin preparation with an alcohol prep pad, a 3.8 cm, 27-gauge needle is used for injection in an out-of-plane approach with localization of the needle done by identification of adjacent tissue movement. An aspiration test before local anesthetic injection is essential to avoid intravascular injection which can be visualized with real-time US. After negative aspiration, 5 mL of a weight-based dose of local anesthetic is injected as close as possible to the ischial tuberosity given its proximity to the pudendal nerve. At injection, the local anesthetic spreads in a medial direction filling the ischiorectal fossa, Figure 2. Infiltration of the ischiorectal space allows for block of the nerves running in the fossa including the pudendal

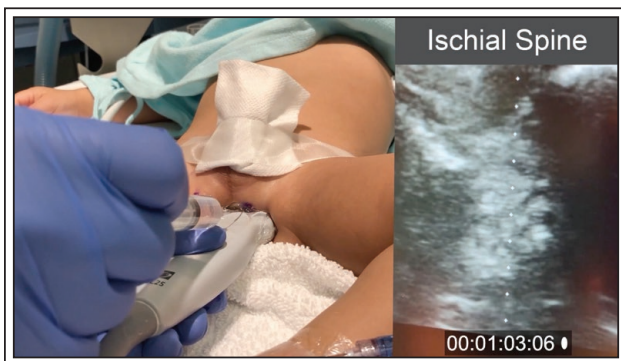

Figure 1. Ultrasound guided pudendal nerve block technique. Prior to injection of local anesthetic, there is adequate visualization of the ischial spine (hyperechoic semicircle with an inferior hypoechoic bone shadow).

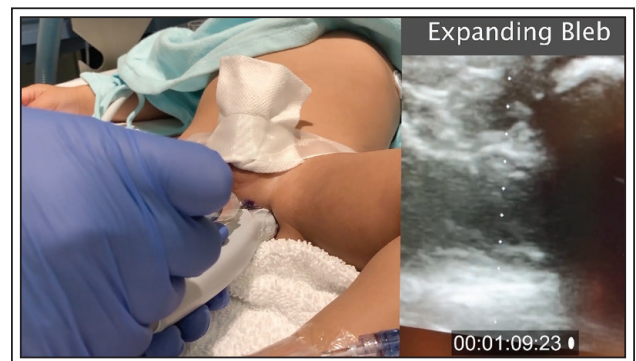


Figure 2. Ultrasound guided pudendal nerve block technique. During injection of local anesthetic there is visualization of an expanding bleb within the ischiorectal fossa.

nerve. The same procedure is then repeated on the contralateral side.

Landmark directed PNB

The initial approach to the landmark-directed technique is similar to that utilized with the ultrasound-guided technique. After general anesthesia induction and airway control, the patient is positioned supine in the “frog leg position” as described above. The index finger is used to palpate the ischial spine along the perineum. After careful skin preparation with an alcohol prep pad, a 3.8 cm, 27-gauge needle is advanced approximately 1 cm inferior and medial to the attachment of the sacrospinous ligament to the ischial spine, where the pudendal nerve transiently leaves the pelvis. Once again, an aspiration test should be performed before local anesthetic injection to avoid intravascular injection. After negative aspiration, 5 mL of a weight-based dose of local anesthetic is injected. The same procedure is then repeated on the contralateral side.

Discussion

The impetus to switch from CEA to PNB came from both clinical scenarios where lower back anatomy precluded CEA and our institutional observations suggesting variable efficacy of CEA. After witnessing the simplicity of a landmark-directed PNB performed by a senior regional anesthesiologist, we adopted this technique. We then began tracking the postoperative analgesic requirements in the post anesthesia care unit (PACU). Our group recently performed a quality improvement project evaluating the comparative effectiveness of PNB compared to CEA. This demonstrated that both ultrasound-guided PNB and landmark-directed PNB were non-inferior to CEA for PACU pain scores, morphine rescue rates and length of stay.¹¹ We have also observed that PNB can be done in less time and lead to more consistent analgesic coverage, however to our knowledge this has not been formally studied.

Pearls for efficient and successful administration of a PNB

For both the ultrasound-guided and landmark directed approach, we have found success with the patient positioned in a generous, widely spaced frog leg position. This position allows for maximal visualization of the perineum, palpation to confirm appropriate landmarks, and adequate space for manipulation of both the syringe used for delivery and the US probe if utilized.

The ability to palpate the ischial spine is fairly consistent across a wide age range. In large individuals and adolescents, we have at times employed a spinal needle to get deep enough to pass medial to the ischial spine.

For the landmark directed approach, stabilization on the medial thigh or on the bed underlying the patient enables and encourages a plane of entry that is parallel or approaching parallel to the ground. We have found that this is the ideal angle of entry and reduces risk of injury/entry to surrounding vasculature. Due to this risk, adjustment of the angle of entry once the needle has entered the skin is not advised.

We recommend direct or near-direct approach to the periosteum of the ischial spine, followed by slight removal of the needle and subsequent medial repositioning into the appropriate space prior to delivery of analgesic agent.

We have further optimized the pudendal nerve block by maximizing the volume of anesthetic given based on the concentration of the anesthetic and the weight of the child. We improved our efficacy by expanding the volume bilaterally, as much as 10mL per side to allow for a larger spread of the anesthetic along the course of the pudendal nerve.

Inherent risks of PNB include inadvertent injury to the rectum or pudendal vessels, however this risk can be mitigated by US guidance.^{12,13} Despite accounts of these rare risks within the literature, we have not seen any intravascular injections nor any hematoma formations using the landmark-directed technique. Rarely, we have identified blood return on aspiration prior to injection of the local anesthetic suggesting needle penetration of a blood vessel, further confirming the necessity and importance of this safety measure. In these instances, we remove the needle, eject the blood-tinged solution, and reintroduce the needle in a separate insertion site, maintaining safe aspiration methods prior to any injection.

Given the effectiveness, lower risk profile and simplicity of approach associated with PNB, we recommend it as an effective alternative to CEA for penile surgeries in pediatric patients. PNB with or without US guidance can be readily adopted and executed by urologists or anesthesiologists prior to penile surgery. Ultrasound-guided PNB represents a safer technique, as it allows for identification of the pudendal artery and visualization of spread of the local anesthetic in the ischioanal fossa during injection, rather than relying solely on negative aspiration to avoid inadvertent vascular injection.

Conclusion

For penile surgery, the PNB represents an alternative regional anesthetic technique that avoids neuraxial access and the potential complications and limitations of CEA. PNB is a simple and effective anesthetic technique with a low risk profile that can be utilized for ambulatory pediatric penile procedures. □

References

1. Goodstein TA, Cost NG, Campbell JB, Vemulakonda V, Wilcox D, Saltzman AF. A contemporary analysis of pediatric urology surgical volume at a tertiary care center. *Urology* 2019;125:179-183.
2. Markakis DA. Regional anesthesia in pediatrics. *Anesthesiol Clin North Am* 2000;18(2):355-381.
3. Adewale L, Dearlove O, Wilson B, Hindle K, Robinson DN. The caudal canal in children: A study using magnetic resonance imaging. *Paediatr Anaesth* 2000;10(2):137-141.
4. Wong GK, Arab AA, Chew SC, Naser B, Crawford MW. Major complications related to epidural analgesia in children: A 15-year audit of 3,152 epidurals. *Can J Anesth* 2013;60(4):355-363.
5. Cyna AM, Middleton P. Caudal epidural block versus other methods of postoperative pain relief for circumcision in boys. *Cochrane Database Syst Rev* 2008;2008(4):CD003005.
6. Tutuncu AC, Kendigelen P, Ashyyeralyeva G et al. Pudendal nerve block versus penile nerve block in children undergoing circumcision. *Urol J* 2018;15(3):109-115.
7. Yang CC, Bradley WE. Neuroanatomy of the penile portion of the human dorsal nerve of the penis. *Br J Urol* 1998;82(1):109-113.
8. Naja ZM, Ziade FM, Kamel R, El-Kayali S, Daoud N, El-Rajab MA. The effectiveness of pudendal nerve block versus caudal block anesthesia for hypospadias in children. *Anesth Analg* 2013;117(6):1401-1407.
9. Kendigelen P, Tutuncu AC, Emre S, Altindas F, Kaya G. Pudendal versus caudal block in children undergoing hypospadias surgery a randomized controlled trial. *Reg Anesth Pain Med* 2016;41(5):610-615.
10. Dickson E, Higgins P, Sehgal R et al. Role of nerve block as a diagnostic tool in pudendal nerve entrapment. *ANZ J Surg* 2019;89(6):695-699.
11. Okoro C, Huang H, Cannon S et al. The pudendal nerve block for ambulatory urology: What's old is new again. A quality improvement project. *J Pediatr Urol* 2020;16(5):594.e1-594.e7.
12. Hecht S, Piñeda J, Bayne A. Ultrasound-guided pudendal block is a viable alternative to caudal block for hypospadias surgery: a single-surgeon pilot study. *Urology* 2018;113:192-196.
13. Gaudet-Ferrand I, De La Arena P, Bringuier S et al. Ultrasound-guided pudendal nerve block in children: A new technique of ultrasound-guided transperineal approach. *Paediatr Anaesth* 2018;28(1):53-58.