

# *How I Do It: Holmium laser cystolitholapaxy and enucleation of the prostate for benign prostatic hyperplasia*

Bruce M. Gao, MD, Seyedamirvala Saadat, BS, Edward J. H. Choi, MD, James Jiang, MD, Akhil K. Das, MD

Department of Urology, University of California, Irvine, Orange, California, USA

---

GAO BM, SAADAT S, CHOI EJH, JIANG J, DAS AK. How I Do It: Holmium laser cystolitholapaxy and enucleation of the prostate for benign prostatic hyperplasia. *Can J Urol* 2024;31(3):11904-11907.

*Holmium enucleation of the prostate (HoLEP) is a gold-standard, size-independent surgical treatment for benign prostatic hyperplasia (BPH) distinguished for its efficacy in tissue removal, shorter catheterization durations, lower transfusion rates, and decreased hospital stays*

*when compared to transurethral resection of the prostate (TURP). The objective of this article is to demonstrate the step-by-step procedure of holmium laser cystolitholapaxy and enucleation of the prostate for BPH, emphasizing a top-down modified two-lobe technique with early apical release which enhances visualization and irrigation flow during the enucleation process.*

**Key Words:** HoLEP, prostate, BPH, cystolitholapaxy, holmium

---

## Introduction

### *Overview of procedure/technology*

Benign prostatic hyperplasia (BPH) is a common disease that increases in prevalence in aging men.<sup>1</sup> The traditional dogma of BPH management is a stepwise approach from conservative management, medical therapy to surgical treatment.<sup>2</sup> Holmium laser enucleation of the prostate (HoLEP) is a size-independent gold standard surgical treatment for BPH that may be performed on anti-coagulated patients.<sup>2</sup> HoLEP involves the use of an end-firing holmium laser fiber and continuous flow rigid cystoscope to endoscopically enucleate the prostatic adenoma within the transition zone from the prostatic capsule. Once the

median and lateral lobes of the prostate are released into the bladder, an endoscopic morcellator device is utilized to remove the prostate tissue from the bladder. A catheter is left postoperatively and the patient may be discharged home the same day or next day with a trial of void. In comparison to transurethral resection of the prostate (TURP), HoLEP results in significantly more tissue removed, shorter catheterization time, lower transfusion rate and decreased hospital stay.<sup>3</sup> In addition, compared to TURP and open simple prostatectomy, HoLEP results in improved AUA Symptom Score (AUA-SS), higher post-operative  $Q_{max}$  and lower retreatment rates.<sup>4</sup>

### *Significant historical studies*

Gilling et al was the first to describe HoLEP in an early clinical experience of 54 patients with a mean age of 70.2. The mean preoperative prostate volume was 75 cc with a mean operative time of less than 1 hour. A mean total of 35.5 grams of tissue was obtained and 93% of patients were discharged home the next day without a catheter. The AUA-SS at 1 month was 8.6 and postoperative  $Q_{max}$  was 23.4 cc/sec.<sup>5</sup> Ibrahim et al conducted a

---

Accepted for publication May 2024

A video clip is available online at [www.canjurol.com](http://www.canjurol.com)

Address correspondence to Dr. Bruce M. Gao, Department of Urology, UC Irvine Health, 3800 W Chapman Ave, Suite 7200, Orange, CA 92868 USA

study over an 18-year period involving 1476 patients with a mean age of 70.7 who underwent HoLEP at a single institution. HoLEP demonstrated significantly improved urinary symptoms, peak flow rate, and post-void residual urine, with a low rate of perioperative complications (0.8%). Postoperative complications included urethral stricture in 1.4% of patients, bladder neck contracture in 2.1%, and blood transfusion in 0.5% of patients. Only 21 patients required reoperation over nearly 20 years, demonstrating the unrivaled long term durability of HoLEP<sup>6</sup>

There are several variations of laser enucleation of the prostate including the classic 3-lobe, modified 2-lobe, and en-bloc enucleation techniques. The enucleation techniques differ in the incisions of the urethral mucosa down to the surgical capsule and the direction of dissection. The modified 2-lobe technique involves enucleating a single lateral lobe and then enucleating the remaining lateral lobe with the median lobe. In our experience, this allows for improved visualization and irrigation flow during the enucleation compared to en-bloc enucleation.

Here, we present our HoLEP technique with the modified 2-lobe, top-down approach and early apical release.

## Method and Technique

### *Patient assessment and preparation*

In the initial evaluation, we obtain a medical history including an International Prostate Symptom Score (IPSS) or AUA-SS. Current bladder management such as intermittent catheter should be known. Past medical history including anticoagulation status should be elicited. Details of any prior prostate surgery with operative reports are noted and physical examination including a digital rectal exam is performed. A urinalysis and prostate-specific antigen (PSA) is ordered to rule out infection and malignancy. Prostate size and shape via transrectal or abdominal ultrasound, or cross-sectional imaging (MRI/CT) is assessed. PVR assessment, uroflowmetry and cystoscopy, although not required, can be considered in select cases. A positive urine culture is treated prior to surgery.

### *Operative technique*

At our institution, we use a 26 French (Fr) continuous flow resectoscope with a laser bridge and endoscopic camera (Karl Storz, Germany). The inflow port is connected to room temperature normal saline irrigation at 60 mmHg and the outflow port is left to gravity drainage. A 7.1 Fr tapered open-ended laser ureteral catheter (Cook Medical) with a silicone

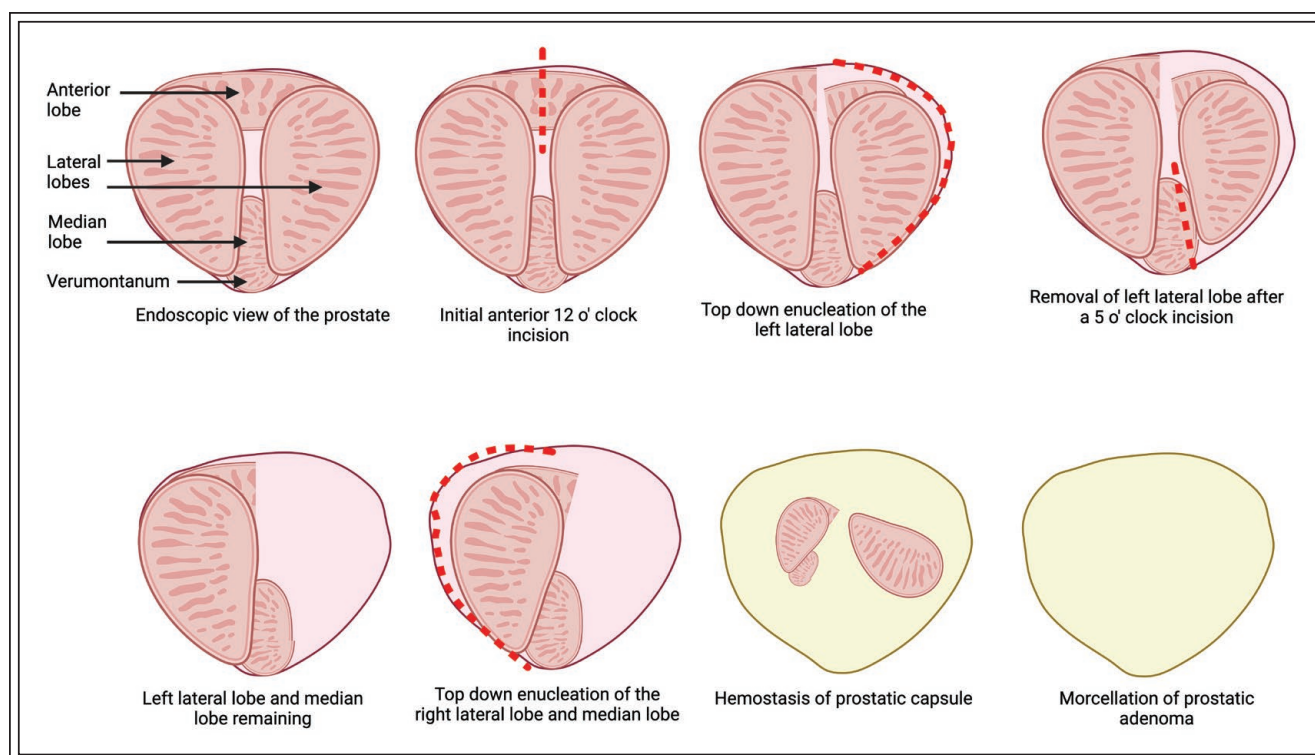
membrane adaptor at the end is passed through the laser bridge which stabilizes the laser at the 6 o'clock position of the endoscope. The silicone membrane adaptor functions to fix the position of the laser fiber from the tip of the endoscope. We use a single-use 550 micron end-firing Holmium:YAG laser fiber (Lumenis Pulse Holmium Laser System with MOSES 2.0 Technology) with an energy level of 2.0J and frequency of 30-50 Hz for both incision and coagulation. A lower frequency is utilized for the treatment of the bladder stone (2.0 J and 25 Hz).

Generally, we perform cystolitholapaxy prior to prostate enucleation. The holmium laser, set at 2.0 J and 25 Hz, is used to dust the bladder stone. Smaller stones are stabilized against the bladder wall and are fragmented using brief laser bursts. The stone debris is then evacuated from the bladder using an Ellik evacuator.

We then turn our attention to prostate enucleation using top-down approach with initial anterior incision and early apical release resulting in a two-piece enucleation, Figure 1. Initial anterior incision is made at the 12 o'clock at the level of the bladder neck and extended distally to the level of the verumontanum while ensuring protection of the external urethral sphincter. This incision is carried down to the prostatic capsule and the right and left lateral lobes are bluntly dissected free from the prostatic capsule with the end of the rigid endoscope. The laser fiber is employed intermittently to further develop the dissection plane along the capsule and release any tethering attachments. Bleeding vessels are managed by withdrawing the laser fibre slightly from the tissue and firing the defocused fibre at the site of bleeding until hemostasis is achieved.

A mid-prostatic urethra to verumontanum 5 o'clock incision is made to the level of the prostatic capsule. The left lateral lobe is further enucleated with the end of the endoscope in a retrograde fashion in a posterior plane towards the bladder neck. The anterior and posterior dissection planes are then joined by incising the remaining distal mucosal bridge between 1 and 5 o'clock. This mucosal strip is accessed via the top-down approach, placing it on stretch and incising it at the 5 o'clock position far away from the urethral sphincter. The left lateral lobe is then further enucleated in a retrograde fashion and then released from the bladder neck into the bladder. Hemostasis is achieved before attention is turned towards the median lobe and right lateral lobe.

An apical release that elevates the distal median lobe is performed with a transverse incision at the level of the verumontanum. The posterior plane of the median lobe and right lateral lobe is further



**Figure 1.** Two-piece prostate enucleation via a top-down approach with initial anterior incision.

enucleated retrogradely with a combination of blunt dissection from the end of the endoscope and the laser. Additional anterior plane enucleation of the right lateral lobe is performed in a similar manner. The remaining mucosal bridge at the distal portion of the right lateral lobe and median lobe is then incised with the laser fibre. Remaining retrograde enucleation is then performed towards the bladder neck until both the median and right lateral lobe are released into the bladder. Hemostasis with the laser is achieved before attention is turned towards tissue morcellation.

Once the two-pieces of prostatic adenoma (left lateral lobe and right lateral lobe with median lobe) are free-floating within the bladder, the endoscope is exchanged for an offset rigid nephroscope (Karl Storz, Germany). A soft tissue morcellator (PIRANHA Enucleation System, Richard Wolf) is placed through the straight working channel of the nephroscope for adenoma morcellation. It is critical a full bladder is maintained through the exchange of rigid scopes and entire morcellation process as decompression can lead to hemorrhage, decreased visualization, and bladder injury. Accordingly, a second irrigation channel is placed with normal saline irrigation to optimize visualization and bladder distention. Suction on the morcellation acts as outflow and to draw the prostatic adenoma to the morcellator blades. Once

the adenoma and morcellator is confirmed to be away from the bladder wall, the blades are activated, and prostatic tissue is extracted. In most cases, all adenoma can be removed with the morcellator, however, a basket can be used to remove any remaining tissue (Perc NCircle Nitinol Tipless Stone Extractor, Cook Medical). The prostatic cavity should be inspected for any remaining tissue fragments and bleeders before instruments are removed from the patient. A 22 to 24 Fr three-way Foley catheter is placed, and continuous bladder irrigation is initiated.

#### *Managing patient postoperatively*

The patient is managed with continuous bladder irrigation with a trial of void the next day. Acetaminophen and ibuprofen are prescribed for pain control and the patient is seen in follow up in 4-6 weeks for pathology review and repeat symptom evaluation. Postoperative Kegels are initiated to assist with early resolution of transient urinary incontinence.

#### Discussion and conclusions

In the recent years, we have seen HoLEP rise in its popularity to treat BPH as it has become the second most chosen treatment modality.<sup>7</sup> Major strengths of

this procedure include its effectiveness independent of gland size, safety in elderly patients or those on anticoagulation, and durable results with low rates of retreatment.<sup>2,4,8</sup> Furthermore, patients report greater satisfaction in quality-of-life metrics with less regret after this procedure.<sup>9</sup> One of the restrictions in HoLEP being widely available is its steep learning curve, with some studies estimating at least 50 cases needed.<sup>10</sup> However, with the clear benefits for patients gained from this technique, we hope that this presentation will aid in garnering interest as well as assist in the learning of HoLEP so that it becomes a mainstay in urologists' armamentarium for BPH. As with any new skill, we encourage you to approach this at a comfortable pace, allowing yourself the time to build experience and confidence. Embrace the learning process, and progressively hone your technique for continual improvement. □

---

#### References

---

1. Berry SJ, Coffey DS, Walsh PC et al. The development of human benign prostatic hyperplasia with age. *J Urol* 1984;132(3):474-479.
2. Sandhu JS, Bixler BR, Dahm P et al. Management of lower urinary tract symptoms attributed to benign prostatic hyperplasia (BPH): AUA guideline amendment 2023. *J Urol* 2024; 211(1):11-19.
3. Chen J, Dong W, Gao X et al. A systematic review and meta-analysis of efficacy and safety comparing holmium laser enucleation of the prostate with transurethral resection of the prostate for patients with prostate volume less than 100 mL or 100 g. *Transl Androl Urol* 2022;11(4):407-420.
4. Michalak J, Tzou D, Funk J. HoLEP: the gold standard for the surgical management of BPH in the 21(st) Century. *Am J Clin Exp Urol* 2015;3(1):36-42.
5. Gilling PJ, Kennett K, Das AK et al. Holmium laser enucleation of the prostate (HoLEP) combined with transurethral tissue morcellation: an update on the early clinical experience. *J Endourol* 1998;12(5):457-459.
6. Ibrahim A, Alharbi M, Elhilali MM et al. 18 years of holmium laser enucleation of the prostate: a single center experience. *J Urol* 2019;202(4):795-800.
7. Guo JN, Mistry NA, Lee MS, Dean NS, Assmus MA, Krambeck AE. Trends of benign prostatic hyperplasia procedures in ambulatory surgery settings. *J Endourol* 2023;37(10):1123-1128.
8. Mmeje CO, Nunez-Nateras R, Warner JN, Humphreys MR. Age-stratified outcomes of holmium laser enucleation of the prostate. *BJU Int* 2013;112(7):982-989.
9. Abdul-Muhsin HM, Tyson MD, Andrews PE et al. Analysis of benign prostatic hyperplasia patients' perspective through a third party-administered survey. *Urology* 2016;88:155-160.
10. Kampantais S, Dimopoulos P, Tasleem A, Acher P, Gordon K, Young A. Assessing the learning curve of holmium laser enucleation of prostate (HoLEP). A systematic review. *Urology* 2018;120:9-22.