

Sacral nerve stimulation for neuromodulation of the lower urinary tract

Chad P. Hubsher, MD, Robert Jansen, MD, Dale R. Riggs, BA, Barbara J. Jackson, BA, Stanley Zaslau, MD

Division of Urology, Department of Surgery, West Virginia University School of Medicine, Morgantown, West Virginia, USA

HUBSHER CP, JANSEN R, RIGGS DR, JACKSON BJ, ZASLAU S. Sacral nerve stimulation for neuromodulation of the lower urinary tract. *Can J Urol* 2012;19(5):6480-6484.

Sacral neuromodulation (SNM) has become a standard treatment option for patients suffering from urinary urge incontinence, urgency-frequency, and/or nonobstructive urinary retention refractory to conservative and pharmacologic treatment. Since its initial development, the manufacturer of InterStim therapy (Medtronic, Inc., Minneapolis, MN, USA), has introduced technical

modifications, while surgeons and researchers have adapted and published various innovations and alterations of the implantation technique. In this article, we feature our SNM technique including patient selection, comprehensive dialogue/evaluation, procedure details, and appropriate follow up. Although there is often great variability in patients with lower urinary tract dysfunction, we maintain that great success can be achieved with a systematic and methodical approach to SNM.

Key Words: neuromodulation, sacral nerve, voiding dysfunction

Introduction

Chronic lower urinary tract voiding dysfunction, specifically overactive bladder (OAB) syndrome with associated urinary urge incontinence, urgency-frequency, and/or nonobstructive urinary retention due to detrusor underactivity, presents a definite therapeutic challenge for the practicing clinician. According to the American Urological Association guidelines, patients should be treated initially with conservative therapies including bladder retraining, pelvic floor exercises, and biofeedback. Along with behavioral modification, second- and third-line treatments involve pharmacologic therapy including oral medication (pain management, anticholinergics,

amitriptyline, cimetidine, pentosan polysulfate) or intravesical instillations (DMSO, heparin, Lidocaine). Despite these efforts, approximately 40% of patients do not achieve an acceptable level of therapeutic benefit, or remain completely refractory to the treatment.¹ In these cases, surgical procedures such as bladder transection, transvesical phenol injections of the pelvic plexus, augmentation cystoplasty, and urinary diversion have been suggested. However, these procedures are associated with significant morbidity and have variable efficacy.

Since receiving approval from the US Food and Drug administration in 1997, sacral neuromodulation (SNM) has become an effective treatment option of voiding dysfunction and has evolved to attain a major role in treating refractory OAB.² The fourth International Consultation of Incontinence (ICI) currently recommends SNM as a second-line treatment of OAB after failed conservative treatment in both men and women. Additionally, the ICI describes the consideration of SNM in the treatment of refractory bladder pain syndrome before extensive surgery.³ In

Accepted for publication July 2012

Address correspondence to Dr. Stanley Zaslau, Division of Urology, Department of Surgery, PO Box 9238, Robert C. Byrd Health Science Center, West Virginia University, Morgantown, WV 26506 USA

2007, a worldwide multicenter trial demonstrated successful SNM treatment 5 years after implantation for 68% of patients with urinary urge incontinence, 56% of patients with urgency-frequency, and 71% of patients with urinary retention.⁴ Considering the challenging patient population, successful SNM treatment is not dependent on surgical technique alone. Factors that are integral to the success of SNM treatment include proper patient selection, extensive pre and postoperative counseling and comprehensive evaluation.

Patient selection

Patients presenting with complaints of lower urinary tract dysfunction need to be comprehensively evaluated prior to considering SNM. At our institution, patient selection begins with a detailed medical history, voiding diary, urinalysis, physical examination (especially with regard to pelvic organ prolapse in females), cough test, cystourethroscopy, and urodynamics. Cystourethroscopy may identify an underlying disorder, such as a bladder calculus or carcinoma in-situ, that should be treated by other means; urodynamics may help to clarify the etiology of the lower urinary tract dysfunction in addition to serving as a baseline for later comparison. Additionally, we attempt conservative treatment consisting of behavior modification, physical therapy, and pharmacologic intervention prior to discussing SNM.³

Once a patient is determined to be an adequate candidate for SNM, we initiate a thorough conversation. We explain that at our institution, we perform the procedure in two stages. Stage I consists of percutaneous placement of temporary wire leads into the S3 foramina. The procedure takes approximately 20 minutes and is performed in the office or operating room under local anesthesia or IV sedation respectively. The trial lasts 1-2 weeks and patients record voiding frequency, voided volume, incontinence episodes and/or changes in catheterization frequency. If > 50% improvement in symptoms occurs, the patient is determined to be a candidate for the second stage. The Stage II procedure involves placing permanent wire leads and an implantable pulse generator. This is performed in the operating room under monitored anesthesia care and local anesthesia. The risks, benefits, and complications of sacral neuromodulation (Interstim), are discussed in detail and include bleeding, infection, pain, unwanted stimulation in the extremities, and the need for battery revision. We quote our institution's long term success rate of the procedure, which ranges from 50%-90% depending on the initial response to testing. Long term efficacy rates are also discussed and the patient is made aware that these are variable and differ

from patient to patient. Additionally, we explain that based on our personal experience, the need for battery replacement is approximately 3 to 5 years after initial implantation. Over the past 5 years our institution has had an infection rate of approximately 5% and a battery/lead revision rate of approximately 25%. We also discuss the possibility of erosion of the battery pack which can occur in 1%-3% of patients. We answer all questions and verify that the patient wishes to proceed.

Pre-procedure instructions

Prior to initiating the Stage I procedure, the patient signs a consent form acknowledging the procedure and various risks and complications associated with it. They are instructed to stop all anticoagulants and antiplatelet agents 7 days prior to the procedure. If the patient has success with Stage I and is determined to be a candidate for Stage II, they then sign a second consent form acknowledging the risks and complications of the Stage II procedure. Again, they are instructed to hold all anticoagulants and antiplatelet agents starting 7 days prior.

Procedure details

Stage I

Based on body habitus and patient preference, this can be performed in the office procedure room under local anesthesia or operating room with intravenous sedation.

- 1) The patient is placed in the prone position with 30-degree flexion at the hips. Their lower back and upper buttocks are prepped and draped appropriately. A surgical transparent film is used to reduce risk of bacterial contamination from the nearby anus, while providing vision to the motor responses of the anus. The hallux is also positioned so that plantar flexion can be observed.
- 2) The coccyx is marked and using a ruler, a line is drawn 9 cm cephalad starting from the gluteal cleft. A horizontal line is then drawn at the 9 cm mark that extends 2 cm on either side of the midline. This represents where the S3 foramina should be located.
- 3) 5 mL-10 mL of 2% local analgesia are infiltrated through the skin and subcutaneous tissue.
- 4) A foramen needle is introduced into the S3 foramina bilaterally. In the office procedure room, this is done without imaging. In the operating room, fluoroscopy is utilized for assistance in locating the S3 foramina with anterior-posterior and lateral imaging.

- 5) Each foramen needle is stimulated separately, noting which needle provides better bellows (contraction of the levator ani muscles causing deepening and flattening of the buttocks groove) and plantar flexion of the hallux. If in the office, sensory responses including paresthesia of the perineal skin and external genitalia, and a "pulling" sensation of the vagina, rectum, or bladder base can be discussed.
- 6) Once appropriate placement of the foramen needle is confirmed, a wire is fed through the needle. The foramen needle is removed and the wires are carefully taped to the patient's back.
- 7) The wires are connected to an external stimulator.
- 8) The patient is discharged home with oral pain medication.

Mid-procedure visit

Approximately 1-2 weeks following the Stage I procedure, the patient returns to the office to discuss their results. If the patient's symptoms improve by > 50% as mentioned above, we consider them a candidate to undergo Stage II. The tape and temporary wires are removed, the Stage II procedure, risks, and complications are discussed in detail, and the Stage II consent form is signed. If, however, the patient's symptoms fail to adequately improve, the temporary wires are removed and the treatment plan is reevaluated.

Stage II

This is always performed in the operating room under fluoroscopic guidance.

- 1) The patient is placed in prone position with 30-degree flexion at the hips. Their lower back and upper buttocks are prepped and draped appropriately. Broad-spectrum antibiotics are administered. A surgical transparent film is used to reduce risk of bacterial contamination from the nearby anus, while providing vision to the motor responses of the anus. The hallux is also positioned so that plantar flexion can be observed.
- 2) The coccyx is marked and using a ruler, a line is drawn 9 cm cephalad starting from the gluteal cleft. Using anterior-posterior fluoroscopic guidance, we identify the SI joints and draw a line to bisect them. The entry points for the percutaneous needles are identified to be 2 cm superior to and 2 cm lateral to the point where the abovementioned lines cross in the midline.
- 3) 5 mL of 2% local analgesia are infiltrated through the skin and subcutaneous tissue.

- 4) A finder needle is then introduced into the S3 foramina bilaterally. Fluoroscopy is utilized for assistance in locating the S3 foramina. We use anterior-posterior and lateral views to identify the foramina and proper needle depth. When placed properly, the needles lie parallel to the vertical axis on A-P imaging and perpendicular to the sacral plate on lateral views.
- 5) Each finder needle is then stimulated separately, noting which needle provides better bellows and plantar flexion of the hallux.
- 6) The side with the stronger clinical response (bellows and hallux flexion) is chosen. Using Seldinger technique, the inner stylet of the foramen needle is removed and a guidewire is placed. The foramen needle sheath is then removed leaving the guidewire in place.
- 7) A #11 blade scalpel is used to make an incision along the guidewire.
- 8) An obturator is placed and its appropriate position is confirmed with fluoroscopy. The obturator's inner stylet is removed and the tined leads are deployed. Fluoroscopy is again used to confirm proper positioning and the leads are checked at 0, 1, 2, and 3 while verifying adequate bellows and hallux plantar flexion. Adequate position of the lead in its final position is imaged in the lateral, Figure 1 and AP views, Figure 2.

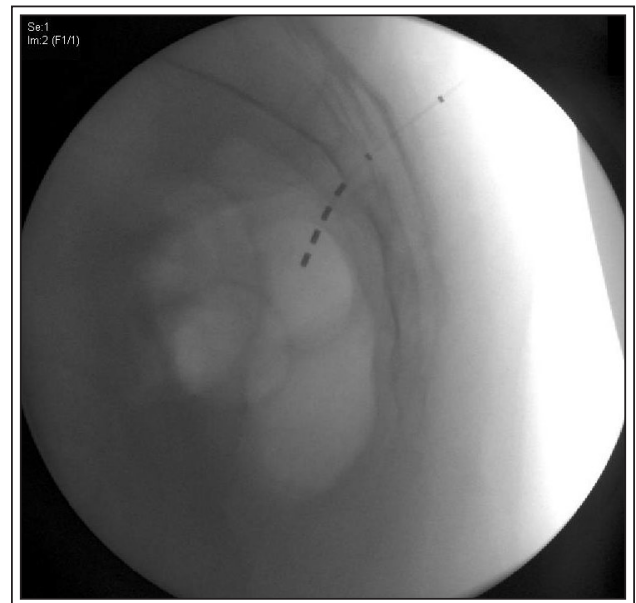


Figure 1. Lateral sacral x-ray showing good position of the lead wire. This patient had their best stimulation of the S3 nerve roots below the inferior border of the sacrum. The lead was affixed in its final position in this location.

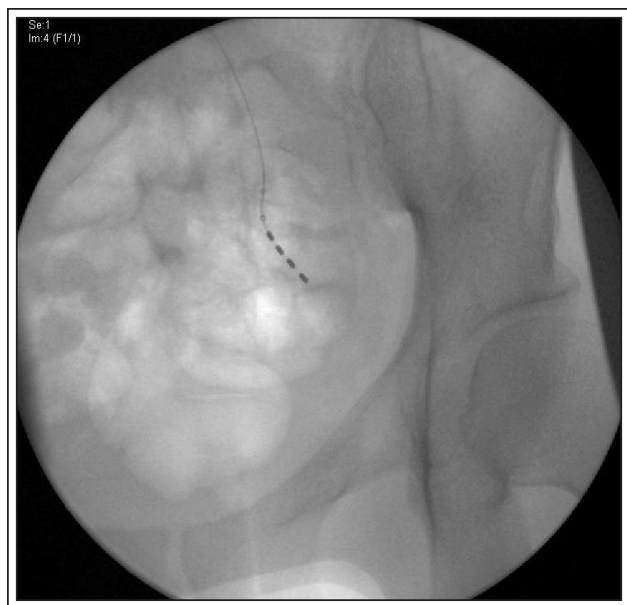


Figure 2. Anterior-posterior view of lead wire in its final position in the S3 nerve root. A gentle curve of the lead wire can be seen as the lead wire parallels the nerve root.

- 9) Next, based on body habitus/shape, a location for the IPG is determined. We prefer to place it below the iliac crest but above the insertion site of the tined lead. A 4 cm transverse incision is made through the skin and subcutaneous tissue to aid in pocket development. Hemostasis is achieved with electrocautery and the wound is irrigated with copious amounts of saline and bacitracin antibiotic solution.
- 10) The tined lead is tunneled to the pocket and screwed into the InterStim IPG with a hex wrench.
- 11) Using the N'Vision programmer, the InterStim IPG is interrogated and impedances are verified to be adequate.
- 12) The IPG pocket is closed in two layers - deep interrupted suture of 3-0 Vicryl and a subcuticular 4-0 vicryl stitch
- 13) In the postoperative area, once the patient has awoken from anesthesia, the InterStim IPG is again interrogated with the N'Vision programmer and settings are determined based on appropriate sensory and motor responses.
- 14) The patient is discharged home with oral pain medication and antibiotics.

Follow up

Our patients follow up in clinic 1-2 weeks after the Stage II procedure for a postoperative check and to

verify that the SNM device is providing results similar to the results experienced with the temporary wires after the Stage I procedure. The N'Vision programmer is also used to interrogate the InterStim device and verify the settings that produce optimal patient sensory and motor response. The patient will then follow up every 6 months, or more frequently if needed.

Discussion

After the patient undergoes the Stage I and Stage II procedure, the external stimulator or IPG must be programmed appropriately to achieve optimal results. Although the manufacturer information extensively describes the use of the patient programmer, to our knowledge there are no algorithms or parameters to follow based on the patient's diagnosis and symptomatology.⁵ The main factors involved in our determination of the proper settings are electrical impedance, frequency and current. The current through the device flows from a negative electrode to a positive electrode – the current is considered unipolar if one electrode is the IPG itself and bipolar if both electrodes are located on the wire lead. The programming device measures impedances between all possible combinations of electrode locations and we use the combination with the lowest impedance that obtains a stimulation effect. Once the electrode combination is chosen, the frequency of the current must be adjusted to further optimize the patient response. During this phase, we most often start with continuous stimulation at 15 Hz, the current manufacturer-recommended frequency, and change the contacts or manipulate the frequency in a meticulous stepwise fashion to obtain optimal results. These settings have not yet been found to correlate with symptomatology and current retrospective review is being undertaken at our institution to determine if a relationship is present.

When discussing SNM with our patients, we explain that the need for battery replacement from battery failure occurs about 3-5 years after initial implantation. According to manufacturer specifications, the Interstim IPG has a battery life of 1.3 amp hours. Their estimated battery longevity based on bipolar settings and high to low energy usage ranges from 2.9 to 5.4 years respectively.⁶ As noted above, the settings used to treat our patient population are quite variable, thus multiple factors may affect the battery life including unipolar versus bipolar current, increased frequency, and amplitude. At this time we are unable to predict how long we may expect a patient's battery to last given their symptomatology though our rate of battery reimplantation seems to align with manufacturer expectations.

Our method involves the placement of unilateral tined leads, though variations of tined lead placement have been explored at other institutions. Although there are few randomized studies available in humans, there is some discussion in the literature of the effects of bilateral versus unilateral SNM. One such study by Sheepens et al found no advantage of bilateral SNM against unilateral SNM, though some patients with nonobstructed urinary retention benefited only under bilateral stimulation.⁷ Additionally, in some retrospective studies, authors have described a possible effect in favor of bilateral SNM.^{8,9} At this time we believe unilateral SNM to be effective in many patients, and in the future we may consider offering bilateral SNM to nonresponders with nonobstructive urinary retention.

In addition to lower urinary tract dysfunction, in recent years, SNM is also being increasingly utilized for fecal incontinence. According to the fourth International Consultation of Incontinence, SNM for fecal incontinence is indicated in patients with an absent, or at most 180-degree anatomic defect of the anal sphincter complex.³ Recently, two different studies reported long term success rates to reach 84% after 2 years and 80% after 5 years.¹⁰ Additionally, SNM is also increasingly being offered to children with urinary of fecal incontinence in the context of clinical trials. However, at this time, the off-label use in children or patients under 16 years of age is still under investigation.

Conclusion

SNM is a minimally invasive, highly effective treatment option for patients with lower urinary tract dysfunction refractive to conservative and pharmacologic interventions. The explanation for how and why SNM works is still not fully understood. Nonetheless, SNM success can be achieved with correct patient selection and a thorough dialogue pertaining to the risks, complications, potential benefit, and expectations from this device. □

3. Abrams P, Andersson KE, Birdir L et al. 4th International Consultation of Incontinence. Recommendations of the International Scientific Committee: Evaluation and treatment of urinary incontinence, pelvic organ prolapse and faecal incontinence. 4th Edition 2009.
4. Van Kerrebroeck PE, Van Voskuilen AC, Heesakkers JP et al. Results of sacral neuromodulation therapy for urinary voiding dysfunction: outcomes of a prospective, worldwide clinical study. *J Urol* 2007;178(5):2029-2034.
5. Medtronic: Manuals and Technical Resources. Available at <http://professional.medtronic.com/pt/uro/snm/prod/interstim-ii/manuals-technical-resources/index.htm>
6. Medtronic: Manuals and Technical Resources. Available at <http://professional.medtronic.com/pt/uro/snm/prod/interstim-ii/features-specifications/index.htm>
7. Sheepens WA, De Bie Ra, Weil EH, Van Kerrebroeck PE. Unilateral versus bilateral sacral neuromodulation in patients with chronic voiding dysfunction. *J Urol* 2002;168(5):2046-2050.
8. Hohenfellner M, Schultz-Lampel D, Dahms S et al. Bilateral chronic sacral neuromodulation for treatment of lower urinary tract dysfunction. *J Urol* 1998;160(3 Pt 1):821-824.
9. Marcelissen TA, Leong RK, Serroyen J et al. The use of bilateral sacral nerve stimulation in patients with loss of unilateral treatment efficacy. *J Urol* 2011;185(3):976-980.
10. Wexner SD, Coller JA, Devroede G et al. Sacral nerve stimulation for fecal incontinence: results of a 120-patient prospective multicenter study. *Ann Surg* 2010;251(3):441-449.

References

1. Oerlemans DJ, Van Kerrebroeck PE. Sacral nerve stimulation for neuromodulation of the lower urinary tract. *Neurourol Urodyn* 2008;27(1):28-33.
2. Schmidt RA, Jonas U, Oleson KA et al. Sacral nerve stimulation for treatment of refractory urinary urge incontinence. Sacral Nerve Stimulation Study Group. *J Urol* 1999;162(2):352-357.